Eur. Urol. 3: 362–367 (1977)

New Developments in the Surgical Treatment of Renovascular Arterial Hypertension[1]

J. Mª. Gil-Vernet, A. Caralps, J. Andreu, L. Revert and D. Tornos
Department of Urology, Barcelona University, School of Medicine, Barcelona

Abstract. Surgery of the renal artery and its branches has not developed at the same rate as the progress made in arterial hypertension renovascular studies. Therefore, the percentage of cure is still low, the mortality rate high and the complications frequent. Based on the experiences in renal allo- and autotransplants, on the progress achieved in different fields, such as extracorporeal kidney surgery, on a new way of approach to the spleen's hilus, on the development of microsurgery and on a better knowledge of the biopathology of vascular grafts, new orientations for this type of surgery are supported. No matter which technique is followed, renal hypothermia by arterial perfusion, elimination of the diseased arterial segment, placement of the kidney in the continuity of another arterial system (auto- or splenorenal transplants), substitution of the transperitoneal approach by the retroperitoneal one, and, in complicated cases, the practice of ex situ arterial reconstruction surgery, is considered fundamental. Statistics, following these guidelines, are presented, which indicates that there were no deaths and that the percentage of success is higher than with classic revascularization surgery.

During this decade, great progress has been made in the study of renal arterial hypertension, and at present time a very defined criteria has been reached regarding exploration, diagnosis, medical treatment and surgical recommendations. However, conventional renovascular surgery has not developed at the same rate. Its surgical techniques have not evolved and, therefore, the percentage of success is still low, the mortality rate is high and unrelated complications frequently occur. These results justify the lack of confidence which the intern has towards this type of surgery.

The belief that the surgical techniques have reached an optimum level, and that in order to improve results a better selection of the patients is necessary, is totally erroneous.

In the last few years, important improvements in revascularization surgery have been achieved, e.g. the experiences obtained in the kidney transplant field, which paved the way to developing local hypothermia methods permitting a safe preservation of the kidney function; the technique of kidney autotransplant with multiple vascular and urological applications; extracorporeal surgery allowing kidney and vessel repair outside the human body; the development of microsurgery; and in addition a new retroperitoneal approach to the spleen's hilus, all of which together with a better knowledge of vascular grafts biopathy, are sufficient reasons to justify a revision of conventional surgical techniques as well as supporting new orientations for the surgical treatment of renovascular arterial hypertension.

The classic revascularization operations are well known to everyone: the endarterectomy, the renoaortic reimplantation, the resectioning and anastomosis, arterial and venous grafts, the patch, the bypass and the splenic-renal anastomosis. The majority of these techniques leave the diseased arterial well in situ, allowing lesions to evolve, and new complications to appear. But the major problem in conventional surgery is the great frequency with which complications such as ischemic tubulopathies, thrombosis, hemorrhages and restenosis occur. From a technical point of view they present very frequently serious difficulties as these arteries

[1] Paper presented to the International Symposium on Diagnosis and Treatment of Arterial Hypertension, Barcelona 1975.

Key Words. Kidney · Renal hypothermia · Renovascular hypertension · Hypertension · Renal artery · Renal autotransplantation

are very small, fragile and affected by the disease and lack sufficient consistency for suture.

Kaufman (7), with reknown experience and authority, affirms that reconstruction surgery cannot be carried out in the kidney vessels as in other vessels nor are all the principles applied in vascular surgery valid for the kidney vessels, in which the vasospasm is frequent and prolonged periods of ischemia tend to give mediocre or poor results. On the other hand, the results of various investigators regarding the biological behavior of the different types of grafts used have provided a better knowledge of its biopathology (6).

Extensive investigations in the last few years have confirmed the knowledge acquired at the beginning of the century, i.e. that incorporated grafts cannot survive. When the vascular wall lacks nutrition, its cellular elements and interstitial substance succumbs to biological decomposition. Structure maintenance is defective and, therefore, so is its function. The involute alterations observed in the graft should be considered as a biological rule instead of a pathological exception. Arterial graft biopathology tends to show that these degenerative processes frequently lead to failure or complications.

We also have knowledge of the biological behavior of the synthetic arterial grafts in the human body after several years. Although their tolerance is really remarkable, an arterial neogenesis is unlikely to take place.

Differentiating synthetic arterial grafts from the internal and external layer is a very complex process and the formation of atheromas, calcifications and other alterations of an involute nature in the new arterial wall seem to confirm the biological rule that all newly-formed connective tissue suffer early degenerative alterations.

Even in those cases where the vascular graft is well incorporated, the circulatory conditions are not physiological because the graft lacks the physical properties of a healthy vascular wall. The slowing down of the flow, the alteration of the vascular wall and the circumscribed hypercoagulability are responsible for the frequent thrombosis which appears hours, days, months or years after the operation.

There is no doubt that the use of synthetic arterial grafts has made possible the great progress which has taken place in vascular surgery by permitting the substitution of the aorta and the large arteries, but this principle is not valid for the kidney vessels.

The results of conventional repair surgery, taken from mass statistics, and from a tensional point of view, do not surpass 60% of success, without taking into account the nephrectomies which are included in these statistics, nor the permanent kidney failure. The operating mortality rate is about 4–19%.

It is evident that the results obtained with the conventional renovascular surgery are very poor. If we want to have safer and more efficient operating methods, with less risk for the patient; if we want to improve the results significantly in accordance with our experience, the following guidelines must be followed: (1) ensure the preservation of the kidney's function; (2) eliminate the diseased segment of the artery; (3) proscribe the use of arterial grafts; (4) use direct reconstruction techniques; (5) place the kidney in the continuity of another arterial system; (6) autotransplant on the right side and splenorenal anastomosis on the left; (7) substitute the transperitoneal approach by the extraperitoneal one; (8) use extracorporeal surgery in special cases, and (9) follow the vascular microsurgery principles.

Protecting the kidney from the effects of ischemia is the most important factor in this type of surgery.

Clamping the renal artery is an obligatory maneuver whatever the technique is, and it can cause two important complications: thrombosis of the small kidney vessels and/or ischemic tubulopathy which are not always reversible when the clamping time exceeds 20 min. These complications cannot be avoided even by heparinizing the patient, nor by placing him in moderate superficial hypothermia nor by provoking an osmotic diuresis.

The in situ arterial perfusion method (fig. 1, 2) that we proposed (1) 4 years ago, helps to avoid thrombosis and tubulopathies and provides the surgeon with all the surgical maneuvering time he requires (even several hours) with the assurance of an immediate and efficient recovery of the kidney function. This revascularization surgery, like other branches of surgery and medicine, have benefitted of the experience in kidney transplants. The autotransplant is good proof of same (8).

The autotransplant is not a technique requiring special training, it is similar to the allotransplant which is widespread. This operation, carried out in accordance with the method which we use (2) in the vascular stage, does not differ from the allotransplant. After sectioning the pedicle, but never the ureter, the kidney (fig. 3–5) is immediately perfused and transferred to the iliac fossa where the vein is anastomosed to the cava vein or to the primary iliac vein and the artery to the hypogastric or external iliac, with the kidney being placed in an inverted position in order to facilitate the vascular anastomosis and achieve better hemodynamic conditions. The ureter should not be sectioned as its length does not cause any drainage problems; in our 120 cases of kidney transplants, the urinary continuity was reestablished by means of pyelopyelic anastomosis, conserving the receiver's entire excretory tract without urinary complications.

The kidney autotransplant contains all the necessary requisites: retroperitoneal operation and

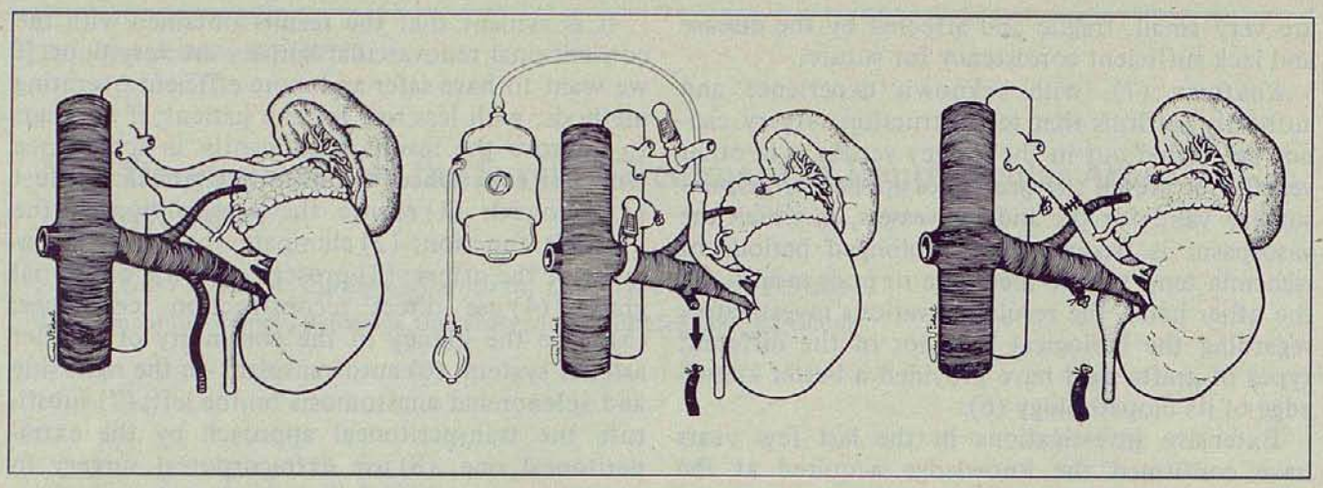

1

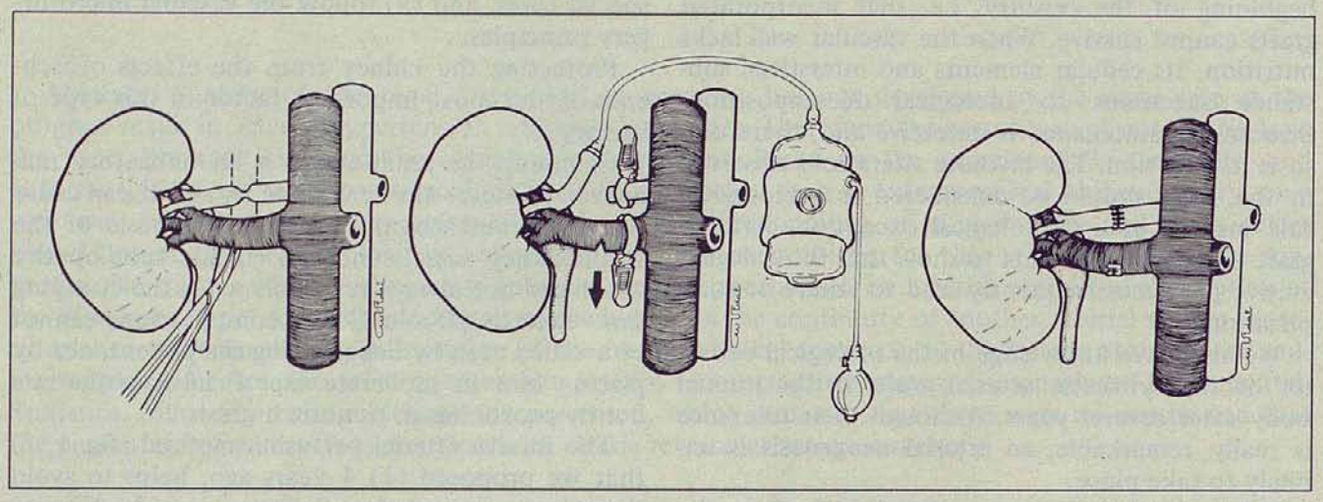

2

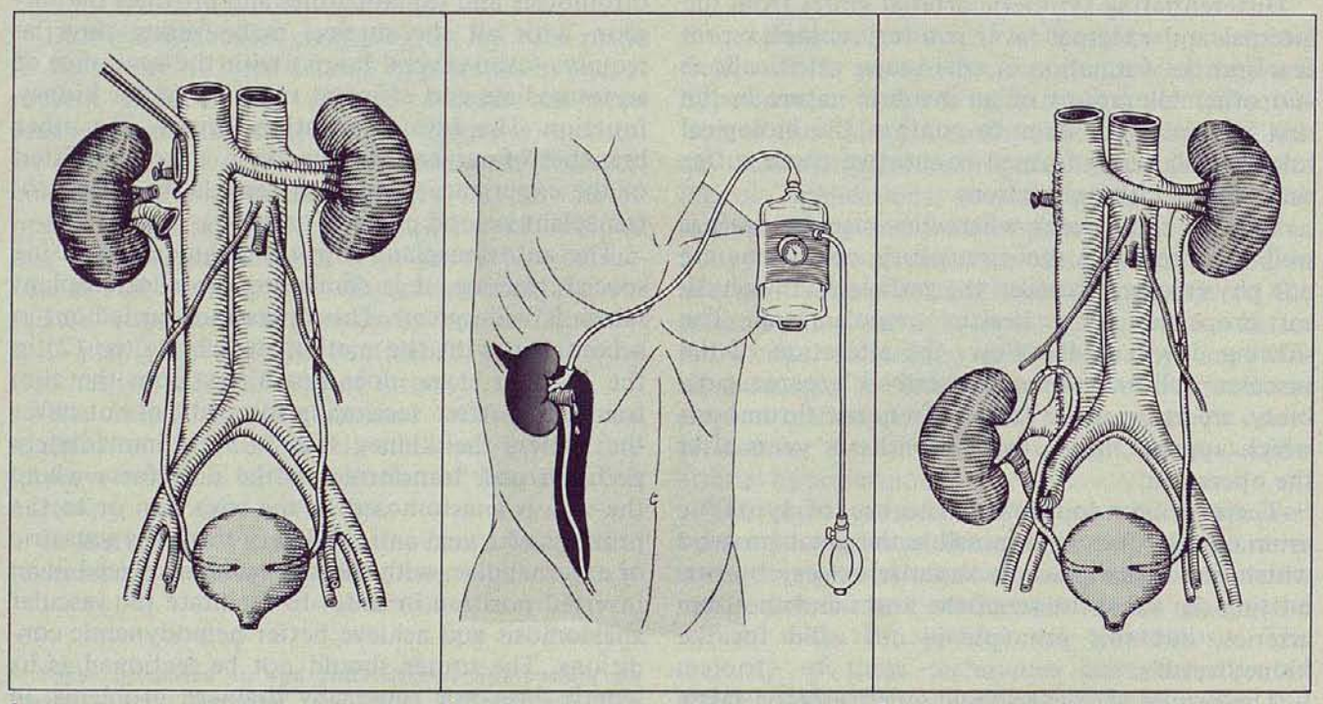

3 4 5

Fig. 1. Left renal hypothermia by means of in situ arterial perfusion and splenorenal anastomosis.

Fig. 2. Right renal hypothermia by means of in situ arterial perfusion, arterial resection and reanastomosis.

Fig. 3. Right kidney autotransplant. Section of the vein and its outlet. Suture of the cava vein.

Fig. 4. Renal hypothermia by means of in situ arterial perfusion and autotransplant.

Fig. 5. Right kidney autotransplant. Anastomosis of the renal vein to the primary iliac vein and the artery to the hypogastric. Redundant ureter does not represent any obstacle for urinary excretion.

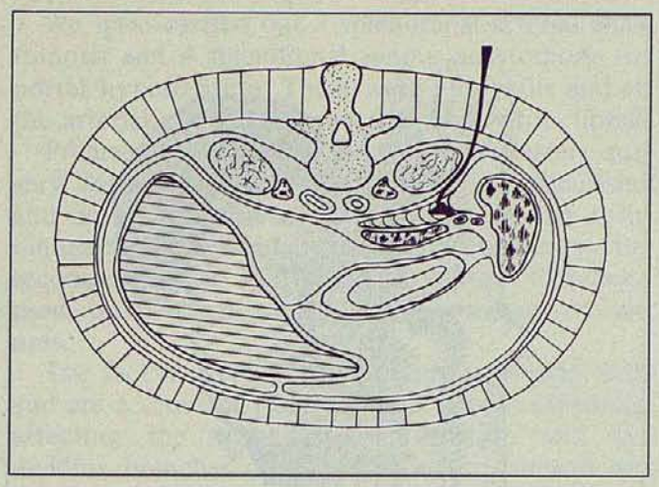

Fig. 6. Horizontal schematic drawing passing through the upper kidney region. An arrow indicates the retroperitoneal way of approach to the spleen's hilus.

easy preservation of the kidney function. It eliminates the diseased section of the artery and is a direct reconstruction method, avoiding biological and hemodynamic graft problems; it also avoids technical problems and is easily adapted to frequent anatomical and pathological variations of the kidney vessels. Technically, the anastomosis of the kidney vessels to the iliacs is easier than the repairing in situ. There is no need to restore anticoagulant treatment during or after the operation.

In 1966, we carried out the autotransplant on both sides indistinctly, but since 1972, when we found a new retroperitoneal way of approach to the splenic vessels, we have used the autotransplant for treating lesions of the right artery and splenorenal anastomosis (when the splenic artery is not stenotic) as well as lesions of the left renal artery. There is an exception to this system: when the lesion is very limited (anular stenosis) and is located in the middle third of a very long renal artery – conditions which rarely occur – resection and reanastomosis is recommended, it can be carried out through the retroperitoneal lumbar way either on the right or on the left side.

The autotransplant may be objectionable in case of generalized atheromatosis, which especially affects the iliac vessels on both sides. If this occurs, an endarterectomy of the iliac artery may be recommended followed by an autotransplant.

Clinical Experience

In accordance with *Smith* (9, 10), our criteria in judging the results is the following: we consider the patients as cured when the arterial pressure is lower than 14–9 after more than a year. The patients classified as improved are those which present an improved response to the medical treatment.

From 1966 up to the present time, we have carried out 36 autotransplants (including 1 case of double autotransplant). The results are the following:

	n	%	
Cured	29	80.5	
Improved	4	11.1	2 (pending operation of the contralateral stenosis) 1 (existence of atheroma in the internal iliac)
Hypertension	3	8.4	1 (coarctation of the aorta) 1 (preterminal chronic renal insufficiency) 1 (pending operation of the contralateral stenosis)
Mortality	0		
Nephrectomy	1	2.7	

It is important to point out that the percentage of cured patients is higher than that obtained when using conventional methods, as well as the absence of any deaths as compared to 4–19% which occurred with conventional surgery. But the most important fact is that there was no decrease in the kidney function as a consequence of the revascularization operation.

In addition to these 36 autotransplants for arterial hypertension, we refer to the 26 autotransplants based on urological recommendations, with only one vascular-type complication which required a nephrectomy. In total, 62 autotransplants with no deaths and only two secondary nephrectomies.

On the left side, we prefer splenorenal anastomosis, which has been used for years, but updated with the new guidelines.

The technique is logical in principle and convincing as it contains some of the requisites which we demand in new surgical practices. However, in accordance with the way it is carried out at present, i.e. transperitoneally, it presents serious problems. The most important factor is the transperitoneal dissection of the splenic artery which entails a great risk of pancreatic lesion; this way also presents difficulties in carrying out the anastomosis due to the depth of the operating field, especially in obese patients.

We have solved all these problems by finding a new retroperitoneal approach (fig. 6) to the spleen's hilus (3). It is a lumbar way and the most direct and least aggressive manner to reach the splenic vessels, there is no risk of pancreatic lesion and it permits a good and simultaneous exposure of the renal-splenic vessels, which facilitates correct execution of the anastomosis. It allows the splenic vessels to be used in their entire length, and avoids tension problems as far as both arterial and venous splenorenal anastomosis are concerned. A splenectomy is not necessary.

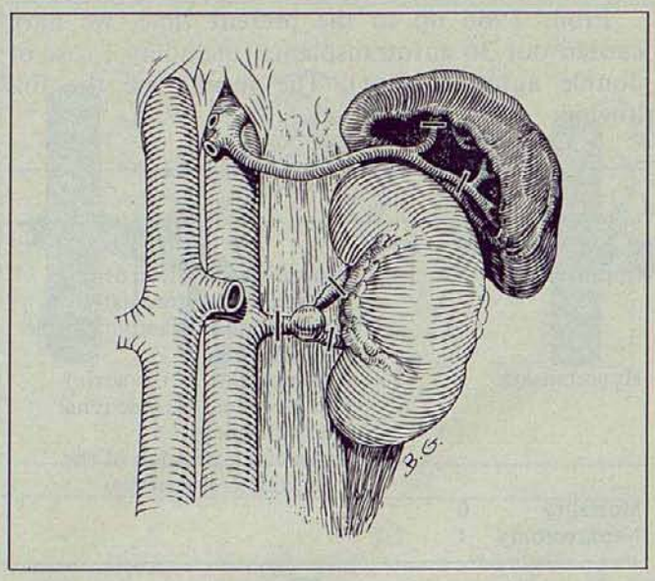

Fig. 7. Stenosis of the renal artery and dysplasia of its dividing branches. Aneurism at the bifurcation level.

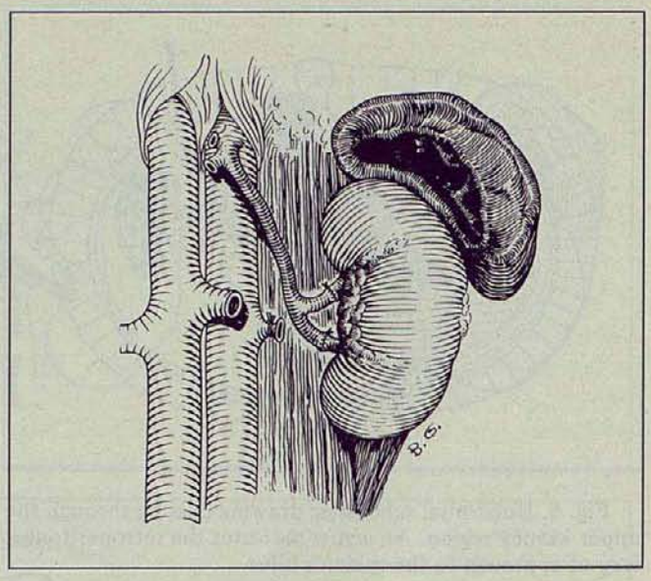

Fig. 8. Substitution of the renal artery and its dividing branches by the splenic arteries by means of retroperitoneal way of approach.

Fig. 9. Renal hypothermia by ex situ arterial perfusion in extracorporeal surgery.

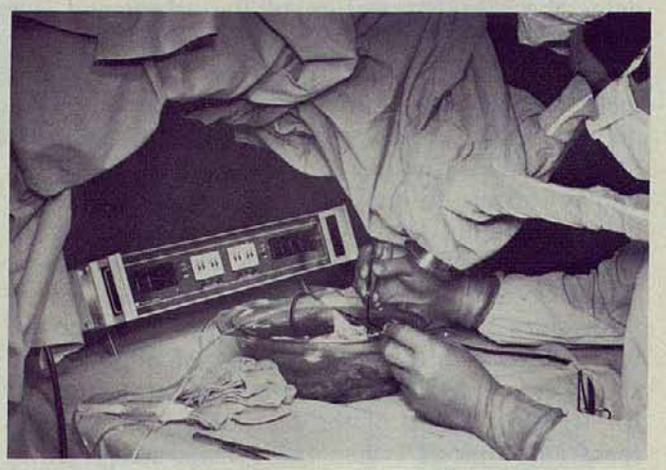

Fig. 10. Vascular microsurgery in ex situ kidney (extracorporeal kidney surgery).

11

Fig. 11. Arterial hypertension due to stenosis in both renal arteries.

Fig. 12. Bilateral renal autotransplant. Note the inverted position of both kidneys. Arterial hypertension cured.

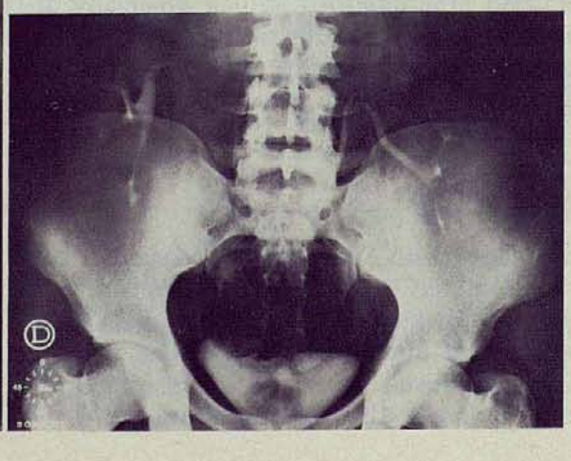

12

We have carried out 8 splenorenal arterial anastomosis and 4 splenorenal venous anastomosis for portal hypertension. There were no deaths and all the arterial and venous anastomosis are functional.

Progress has also been made in renal artery surgery for aneurisms (4). In treating the aneurisms and associated lesions, the same or similar techniques recommended by conventional surgery for reconstruction of the renal artery trunk have been used, but with an even higher percentage of failures.

The fact that most aneurisms are associated with and are a cause of fibromuscular arterial dysplasia, affecting the trunk, the bifurcation and the dividing branches of the renal artery, suggest undoubtedly that the most logical surgical procedure is to substitute the artery trunk and the bifurcation as well as the dividing branches. We have achieved substitution of this vascular crossroad by using the splenic artery with its bifurcation and dividing branches at the spleen's hilus level, in an extraperitoneal manner by means of the new approach described above and without the need to carry out a splenectomy (fig. 7, 8).

Finally, extracorporeal kidney surgery (5), a recent and important advance in surgery, has made possible the repair of the kidney and its vessels (fig. 9, 10) outside the human body, in those lesions of small dividing branches of the renal artery, aneurisms or arteriovenous fistulas where – because of their intrasinusal situation – in situ repair was impossible.

Following the above guidelines, surgery of the renal artery and its branches has been simplified, improving the percentage of success and reducing the death rate as well the complications. A greater number of patients can, therefore, take advantage of this surgery which is gaining the intern's confidence.

References

1 Gl-Vernet, J.Mª.; Caralps, A.; Vidal, Mª.T.: Nuevo método para la preservación del riñón en cirugía vasculorenal. Cir. Esp. *2:* 179 (1972).

2 Gil-Vernet, J.Mª.; Caralps, A.; Revert, L.; Vidal, Mª.T.; Carretero, P.: Autotransplantation du rein pour hypertension artérielle. P.v. 63e congr. Ass. fr. Urol., p. 467 (1969).

3 Gil-Vernet, J.Mª.: Progress in renal vascular surgery. 16th Congr. ISU, Amsterdam 1973.

4 Gil-Vernet, J.Mª.: Communication at the 7th International Course of Urology, Barcelona 1976.

5 Gil-Vernet, J.Mª.; Caralps, A.; Revert, L.; Andreu, J.; Carretero, P.; Figuls, J.: Extracorporeal renal surgery. Urology *4:* 444 (1975).

6 Heberer, G.; Rau, F., Lörh, H.H.: Enfermedades de la aorta y de las grandes arterias (Científico Médica, Barcelona 1970).

7 Kaufman, J.J.: Results of surgical treatment of renovascular hypertension: an analysis of 70 cases followed from 1 to 6 years. J. Urol. *94:* 211 (1965).

8 Serrallach-Mila, N.; Paravisini, J.; Alberti, J.; Mayol-Valls, P.; Casellas, A.; Torner-Soler, M.; Nolla-Panadés, J.: Nuevo método de revascularización en la cirugía de la hipertensión renovascular en el autotransplante renal. Angiologica *18:* 93 (1966).

9 Smith, H.W.: Hypertension and urologic disease. Am. J. Med. *4:* 724 (1948).

10 Smith, H.W.: Unilateral nephrectomy in hypertensive disease. J. Urol. *76:* 685 (1956).

Prof. J. Mª. Gil-Vernet, Cátedra de Urología, Facultad de Medicina, Universidad de Barcelona, Casanova 143, Barcelona-11 (Spain)