

NEW SURGICAL APPROACH FOR TREATMENT OF COMPLEX VESICOVAGINAL FISTULA

J. M. GIL-VERNET, A. GIL-VERNET AND J. A. CAMPOS

From the Department of Urology, Hospital Clinic I Provincial, University of Barcelona, Barcelona, Spain

ABSTRACT

Complex vesicovaginal fistulas still represent a management problem, since most of the cases have been operated on previously and because of the lack of a completely successful surgical technique. A new procedure for vesical autoplasty is presented. A flap is obtained from the posterosuperior bladder wall that slides down to cover large lesions, even in low capacity reservoirs. The technique has shown excellent long-term results in 42 consecutive complicated cases. (*J. Urol.*, 141: 513-516, 1989)

Many reports on the closure of vesicovaginal fistulas have described the repair method and surgical approach. The different surgical tactics and multiple techniques reported are partially influenced by the etiology, topography and medical speciality of the surgeon.

There seldom is a problem in the surgical repair of small and simple vesicovaginal fistulas that have not been operated on previously, are far from the bladder neck or ureteral meatus and do not show changes in bladder texture. These fistulas are treated through a vaginal approach by the gynecologist. This type of defect is cured merely by freshening the edges, fulguration or tissue resection with a 2-layer closure. However, fistulas treated by the urologist are complex, complicated and multioperated, have an important structural change in the perifistulous tissue and are close to the ureteral meatus or bladder neck, sometimes with loss of substance and a significant decrease in bladder capacity or alterations in the bladder wall secondary to irradiation. A reliable technique for repair of complex fistulas has not yet been described.

We propose a new procedure of vesical autoplasty in which a flap obtained from the posterosuperior bladder wall slides down to cover the diseased area. This simple and sure method was successful in a consecutive series of 42 complex vesicovaginal fistulas of different etiologies.

TECHNIQUE

The approach can be either transvesical, extraperitoneal or transperitoneovesical. The bladder is incised transversely through the dome (fig. 1, A), which provides for good exposure of the lesions (fig. 1, B). Both ureters are catheterized for easier identification and protection during tissue excision and closure (fig. 1, C). Placement of stay sutures (fig. 1, D) to include the fistulous orifice and surrounding fibrous tissue, which is especially abundant in reoperated cases, simplifies a wider marginal excision. This surgical stage is fundamental. The excision must be extended to reach well vascularized and healthy bladder wall. Often after a wide débridement the submucosal segment of the ureter remains close to the edge of the resection and only in rare cases does this make reimplantation necessary.

During dissection and development of the tissue layers involved in the fistula the plane between the vaginal and bladder walls should be detached carefully. Precise hemostasis of the vaginal vessels must be practiced, always avoiding electrocoagulation. A 1-layer interrupted suture of the vaginal wall is important with inversion of the edge towards the cavity (fig. 2). The sutures are separated enough to drain any hematoma

that might form in a third space between the vesical and vaginal walls. Such a space is absent when an omental graft is left in place.

For closure of the resected area a flap is obtained through a bilateral, symmetrical, divergent incision from the superior edge of the defect directed towards the bladder dome with a previous peritoneal detachment (fig. 3, A and B). A transperitoneovesical approach is necessary when hysterectomy has been performed or is the cause of the fistula. An incision through the cul-de-sac allows for flap advancement (fig. 3, C). The flap with a wide superior base is brought down easily towards the bladder neck and approximated with interrupted 3-zero catgut sutures in 1 layer (fig. 3, D). Each suture includes the muscular and submucosal layers exclusively (fig. 4, A), and the distance between them should not be less than 10 mm. After all sutures have been placed the ureteral stents are withdrawn (fig. 4, B). These sutures do not contact the vaginal closure (fig. 4, C). When the approach has been transperitoneal the greater omentum or the epiploic appendages of the sigmoid colon are interposed between the vesical and vaginal walls.

Closure of the cystotomy is in a single extramucosal layer. An 18F Foley catheter is left for 6 to 7 days (fig. 4, C). A film of the procedure is readily available.

RESULTS

From January 1980 to July 1987 we treated 42 complex fistulas with the aforementioned procedure. Mean patient age was 37 years, with a range of 32 to 60 years. There were 28 fistulas secondary to a gynecological operation, 11 from an obstetrical cause and 3 secondary to irradiation. All fistulas were operated on previously at other hospitals (once in 6 cases, 2 times in 18, 3 times in 17 and 7 times in 1). There were 2 vesicovaginal fistulas and 8 patients had a significant decrease in bladder capacity (see table). In every case the sphincteric mechanism was intact. Immediate closure was obtained in 100 per cent of the patients without recurrence since we started using this technique.

DISCUSSION

Former classification of upper and lower urinary fistulas has been replaced by simple and complex terminology. The latter types are by definition previously operated cases next to the ureteral meatus or bladder neck and while the defect may be large or small it usually is in the middle of a dense sclerotic area. Repair of the simple vesicovaginal fistula does not entail major difficulties and the vaginal or vaginoperineal approach is preferred. However, for treatment of complex fistulas the

Accepted for publication August 17, 1988.

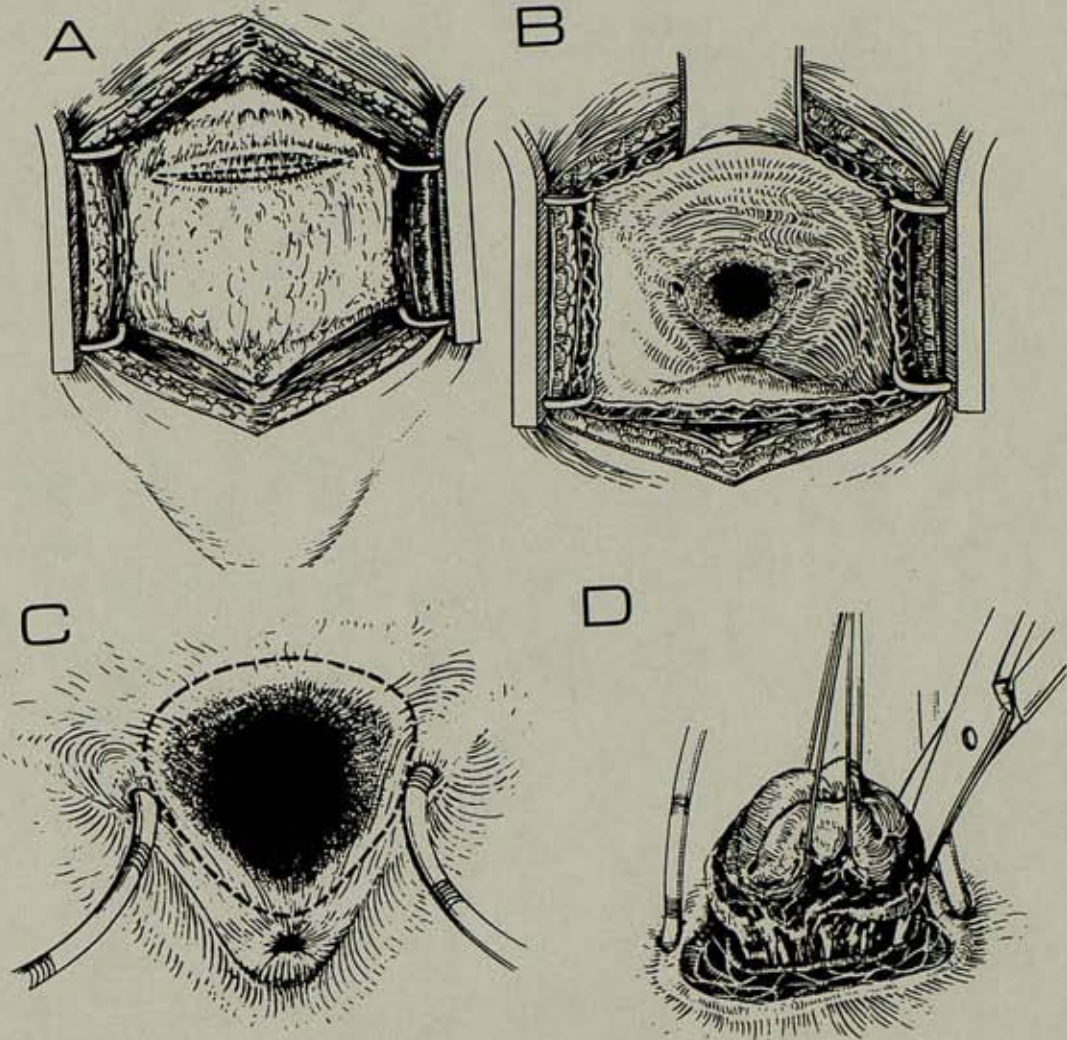


FIG. 1. A, abdominal approach shows transverse cystotomy through bladder dome. B, wide exposure of lesions shows ureteral meatus, bladder neck and substance loss. C, ureteral stenting. Broken line corresponds to fistulous and perifistulous tissue to be resected. D, stay sutures simplify wide and necessary resection of edges.

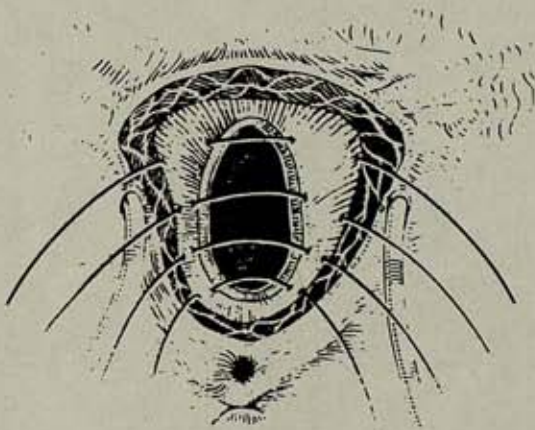


FIG. 2. Vaginal wall inversion

transvesical or Legueu¹ transperitoneovesical approach offers a better exposure of the lesions and greater technical possibilities. The latter method provides for fast and direct access to the fistula. The fibrous tissue resection is performed under visual control and ureteral stenting is done easily, which allows for adequate identification and preservation of the submucosal ureteral portion.

Of greater importance is the method to repair these complex fistulas. After wide resection of the perifistulous fibrosclerotic tissue and the mandatory vesicovaginal tissue plane separation, a wide defect is left next to or close to the ureteral meatus or bladder neck, sometimes in a reduced capacity reservoir. Under these circumstances the surgeon cannot perform an edge-to-edge anastomosis and the resected area must be replaced by an omental or bladder flap. The latter is the most physiological, natural and secure. We believe as does Couvelaire that "the bladder is better closed with bladder".²

To replace the substance loss a vesical autoplasty was proposed in 1954 by Cafer-Yildiran, who obtained a flap from the posterior bladder wall composed of mucosa and the inner half of the muscle layer.³ The bladder flap and its base were slid down until the defect was completely covered and 2-layer suturing was performed. However, much labor was required and the posterior layer remained under tension, which explained the immediate success rate of only 64 per cent. During 1965 Kuss and Chatelain described an autoplasty technique that obtained the flap from the anterosuperior wall and required a longitudinal hemisection.⁴ This approach is possible only when the reservoir preserves a good capacity, which is an infrequent occurrence. A drawback is that vascularization of the distal edge of the flap might be compromised and also be traumatic due to the wide bladder mobilization.

Our vesical autoplasty differs from others described previ-

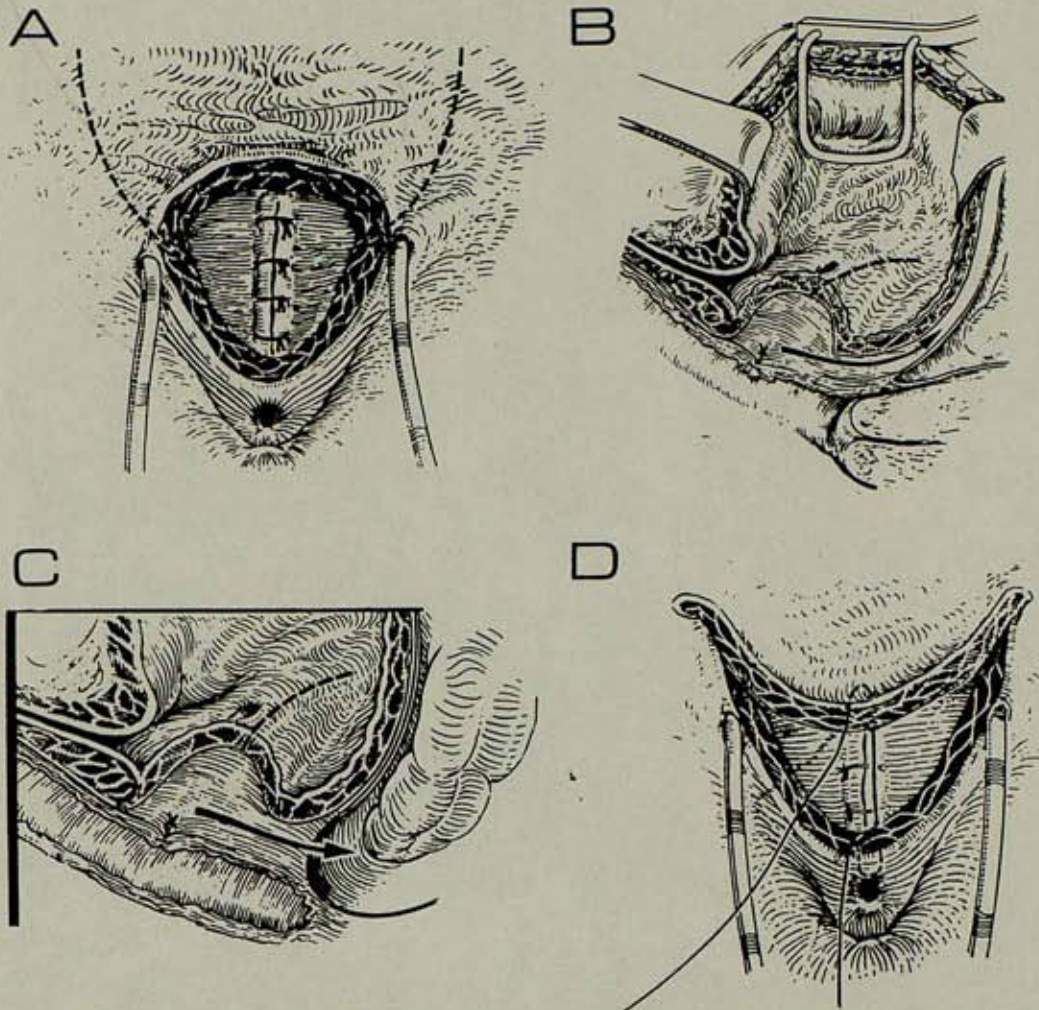


FIG. 3. A, autoplasty. Flap is obtained from 2 bilateral, symmetrical divergent incisions towards bladder dome. B, lateral view of extraperitoneal approach with bladder dome detachment from peritoneum. C, transperitoneovesical approach. When uterus is absent incision through cul-de-sac allows for peritoneovesical flap advancement. D, view of correct method of flap suture, excluding mucosa.

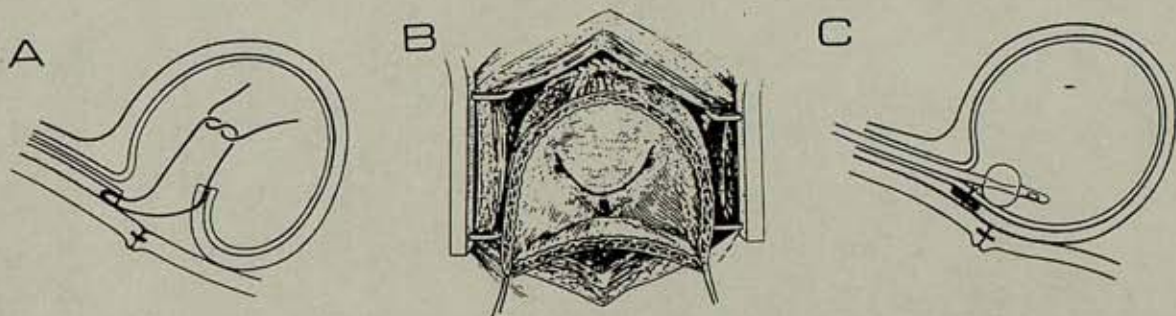


FIG. 4. A, flap advancement towards bladder neck. B, finished closure of lesion. C, lateral view depicts unmatching of sutures in each wall

Analysis of results

Etiology	No. Pts. (%)	No. Reoperations (No. pts.)
Gynecological operation	28 (66.7)	1 (4), 2 (15), 3 (8) and 7 (1)
Obstetrical	11 (26.2)	1 (2), 2 (1) and 3 (8)
Irradiation	3 (7.1)	1 (0), 2 (2)* and 3 (1)*

* One patient in each group had a vesicovaginorectal fistula.

ously in that the flap is obtained from the posterosuperior bladder wall and it is able to slide down even when a large fistula is present. Due to the wide base it is well vascularized and can be obtained also when the volumetric capacity is decreased markedly. This technique provides the trigonal area with all of the healthy tissue required. There are no limits in size or topography and it is impossible only in the case of a small, retracted bladder composed of dense sclerotic tissue secondary to irradiation. We treat those cases by augmentation

enterocystoplasty, which restores satisfactory voiding function.^{5,6} At present only the fistulas associated with destruction of the sphincteric mechanism represent difficult cases that require a different type of surgical management.

REFERENCES

1. Legueu, F.: De la voie transpéritonéo-vésicale pour la cure de certaines fistules vésico-vaginales opératoires. *Arch. Urol. Clin. Necker*, 1: 1, 1914.
2. Couvelaire, R.: Les fistules vésico-vaginales complexes. *J. d'Urol.*, 88: 353, 1982.
3. Cafer-Yildiran: Deux techniques personnelles dans la cure des fistules urogénitales. Lambeauplastie vésicotrigonale et Lambeauplastie vaginale inversée. *J. d'Urol.*, 60: 144, 1954.
4. Kuss, R. and Chatelain, C.: Une technique de cystoplastie par Lambeau dans le traitement des vastes fistules vésico-vaginales. *Mém. Acad. Chir.*, 91: 142, 1965.
5. Gil-Vernet, J. M.: El trasplante intestinal en cirugía urinaria. Ponencia al VI Congreso de la Asociación Española de Cirujanos. *Cir. Gin. Urol.*, 17: 314, 1963.
6. Gil-Vernet, J. M. and Vergallo, E.: La colocistoplastia nella terapia delle fistole vesico-vaginali "incurabili". *Riv. Ita. di Ginec.*, 42: 302, 1959.