

## TECHNIQUE FOR CONSTRUCTION OF A FUNCTIONING ARTIFICIAL BLADDER

J. M. GIL VERNET\*

*From the Department of Urology, School of Medicine, University of Barcelona, Spain*

Having been very much impressed by the results obtained with use of a segment of the sigmoid colon as a partial substitute for the urinary bladder (colo-cystoplasty), we decided to perform total substitution of the cancerous bladder with an isolated segment of the sigmoid colon anastomosed to the urethra, thus obtaining a functional artificial bladder from which the patient would void through this natural outlet and also be spared the severe complications frequently observed after ureterosigmoidostomy without diversion of the fecal stream.

We are aware of experimental and clinical data from several authors who have been using ileum in such cases, although the results are not too encouraging. These results are explained when we consider the inadequacy of the small bowel not only as a total substitute for the urinary bladder but also for enlargement, as in ileo-cystoplasty.

Our experience now covers 15 cases of malignant tumors of the bladder and recurring diffuse papillomatosis; we are also presenting the techniques used in these cases.

This surgical technique planned by us is entirely different, as far as we know, from those described up to the present time. It was conceived after seeing the results obtained from other types of colo-cystoplasty for the enlargement of the so-called contracted bladder with a segment of the sigmoid colon. We have performed our type of colo-cystoplasty in a series of 30 cases without mortality and with perfect restoration of normal micturition. These results made us realize the tremendous possibilities of an isolated segment of the sigmoid colon, so much so that in the near future we think we might have a proper substitute for the cancerous bladder from both the anatomical and functional standpoints.

We consider of capital importance the selection of the intestinal segment, because from its activity depends the postoperative functional

results. We positively disregard the use of ileal segments for construction of an artificial bladder because of their poor contractile power to expel urine, small volumetric capacity, excessive mucus formation, possibilities of invagination and of obstruction, the electrolyte disturbances due to reabsorption (typical physiological property of the ileum) and shortness of the mesentery. A comparative study of the use of the sigmoid in the execution of enterocystoplasty has already been published in collaboration with R. Gosalbez.<sup>1</sup>

Technically speaking, the ideal intestinal segment for the construction of an artificial bladder is the sigmoid colon.

The first case of total cysto-prostato-vesiculectomy, followed by construction of a functioning artificial bladder with an isolated sigmoid segment anastomosed to the membranous urethra, was done in a one stage operation, on June 4, 1957 in the Department of Urology, School of Medicine, University of Barcelona, on a 64-year-old patient with bladder carcinoma. The postoperative results were very satisfactory, as we now see this patient at the present time with a completely normal urinary tract and perfect voiding control (figs. 1 and 2).

We have already performed this operation on 15 patients. The late results obtained will be the subject of another paper. Here, we shall limit discussion to a description of the different techniques that have been followed.

Preoperative preparation of the intestine is the same as for a segmental colectomy or a colo-cystoplasty.

It is of great importance to study and have a perfect control of the pre- and postoperative status of the patient, from which will depend the good postoperative results. A perfect water and electrolyte balance should be obtained with a determination of plasma protein as well. On the other hand, we have to avoid the imbalance that

Accepted for publication January 29, 1959.

\* Translated into English by Dr. J. P. Bourque, Montreal, Canada.

<sup>1</sup> Gil Vernet, J. M. and Gosalbez, R.: Ileo-cystoplasties ou colo-cystoplastie. *J. d'uro.*, **63**: 466, 1957.



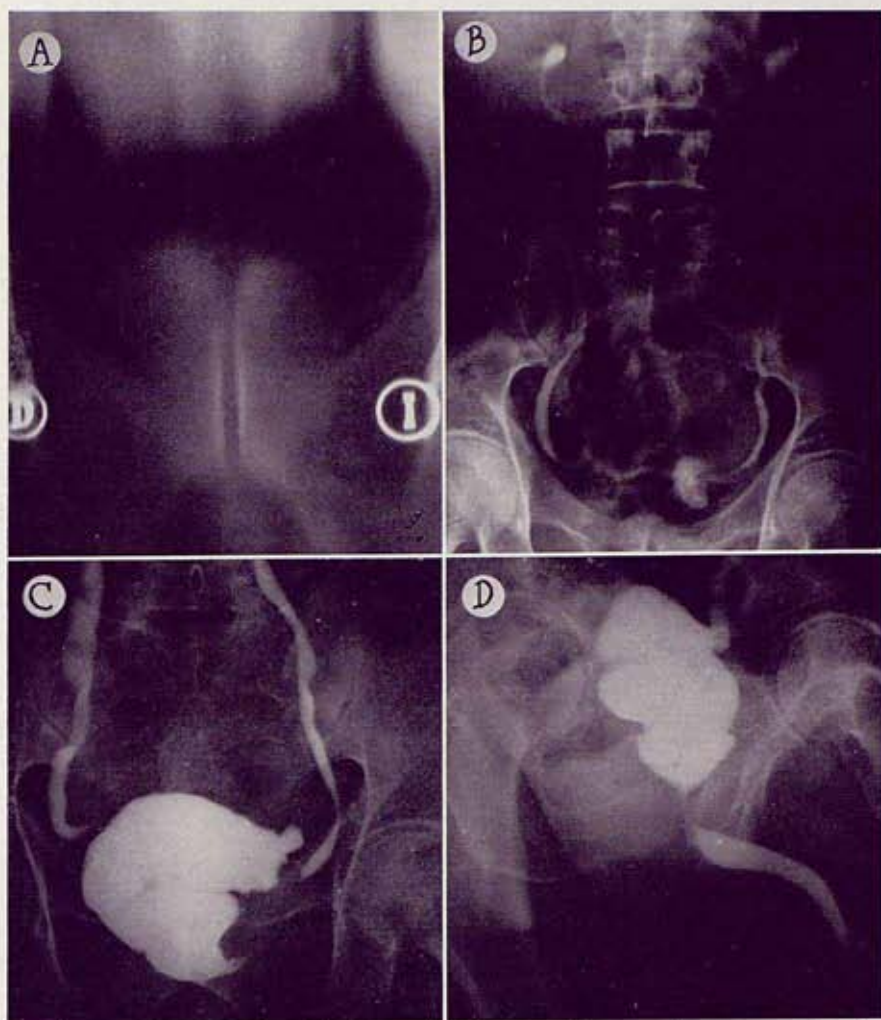


FIG. 1. Case 1. Technique No. I used (end-to-end). Anastomosis at membranous urethra. A, preoperative planigraphy. Infiltrating tumor of dome, neck and vesical trigone. B, excretory urogram 1 year after operation. C, retrograde cystourethrogram to maximum capacity (1 year following operation). Slight ureteral reflux. D, oblique cystourethrogram.

goes along with the postoperative illness, the renal involvement (with an already diseased kidney in many cases) and the continuous suction; parenteral nourishment and hydration have to be kept under control for they can promote by themselves failure of the operation performed with perfect technique. These precautions which are per se very important in any given abdominal operation are far more important in this instance when the large bowel is being used as a bladder substitute.

Finally, the patient's nutritional status, usually an elderly person in the majority of cases, in poor general condition due to tumor, is a fact that has

to be considered in order to choose the proper time for the operation; also, we have to be very careful in the preparation and more so in the immediate postoperative period of 10 to 15 days.

The intestinal segment can be anastomosed to different urethral levels according to the type of vesical lesions and their localization; therefore, in performing the block excision of the bladder and of the prostate gland, the division of the urethra can be performed as follows (fig. 3):

A) Immediately above the verumontanum, thus not disturbing the seminal vesicles.

B) Below the verumontanum, anastomosing the bowel segment to the apex of the prostate.



C) Immediately below the apex of the prostate with the anastomosis made to the membranous urethra.

Anastomosis between the urethra and the intestinal segment can be either end-to-end or end-to-side.

TECHNIQUE NO. 1 (EXTRAPERITONEAL END-TO-END ANASTOMOSIS)

A) *Excision.* A midline abdominal incision from the umbilicus to the symphysis pubis is made and held by a large autostatic retractor, lymphadenectomy of the internal iliac chains is carried out, and total cysto-prostato-vesiculectomy<sup>2</sup> is performed by our extraperitoneal technique taking care to do an elliptical division of the ureters as they enter into the bladder (fig. 4). When the prostatic urethra appears to be intact, because the tumor is far away from the vesical neck, we prefer to salvage the apical portion of the prostate in order to preserve the integrity of the external sphincter. In some cases the excision is complete and the intestinal segment is being anastomosed to the membranous urethra, thus preserving also a good urinary control.

In cases where there is a large prostatic adenoma, it is better to do the enucleation so as to avoid any obstruction to the new bladder. If the seminal vesicles are being excised it is better to avoid the prostato-peritoneal aponeurosis and also the serosa which protects the rectum because they can be used for the first posterior layer thus suturing the serosa of the intestinal segment to the aforementioned aponeurosis. When the excision has been finished, both ureters are catheterized and ureteral catheters are placed outside the operating field. The pelvic cavity is then packed with a warm moist laparotomy pad dipped in normal saline solution.

B) *Construction of the intestinal segment into a neo-bladder.* The same intestinal technique that we follow in performing simple colo-cystoplasty is used with the exception that for construction of the artificial bladder, the length of the intestinal segment must be longer, that is, 28 or 30 cm.

Although in simple colo-cystoplasty, the sigmoidal segment can be anastomosed to the trigone without tension due to the fact that the remaining portion of the bladder has some mobility which permits it "to go" to the intestinal

<sup>2</sup> Gil Vernet, J. M.: Cystectomie totale et implantation urétéro-rectale par voie extra-péritonéale. J. d'uról., 58: 359, 1952.

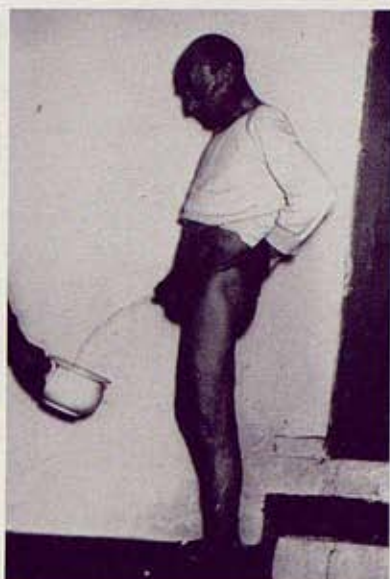

FIG. 2. Case 1. Patient during act of micturition (1 year following operation). Micturition every 2 to 3 hours. Perfect urinary control at daytime and slight nocturnal incontinence.

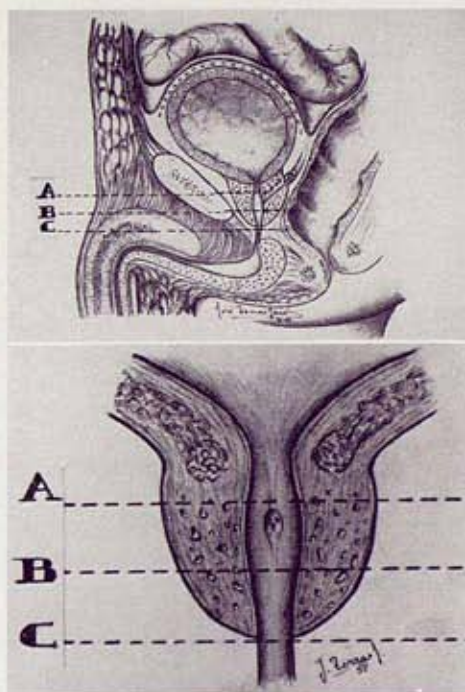


FIG. 3

segment, in this operative technique it is the intestinal segment which has to move forward more deeply until it reaches the membranous urethra or the apex of the prostate; in this



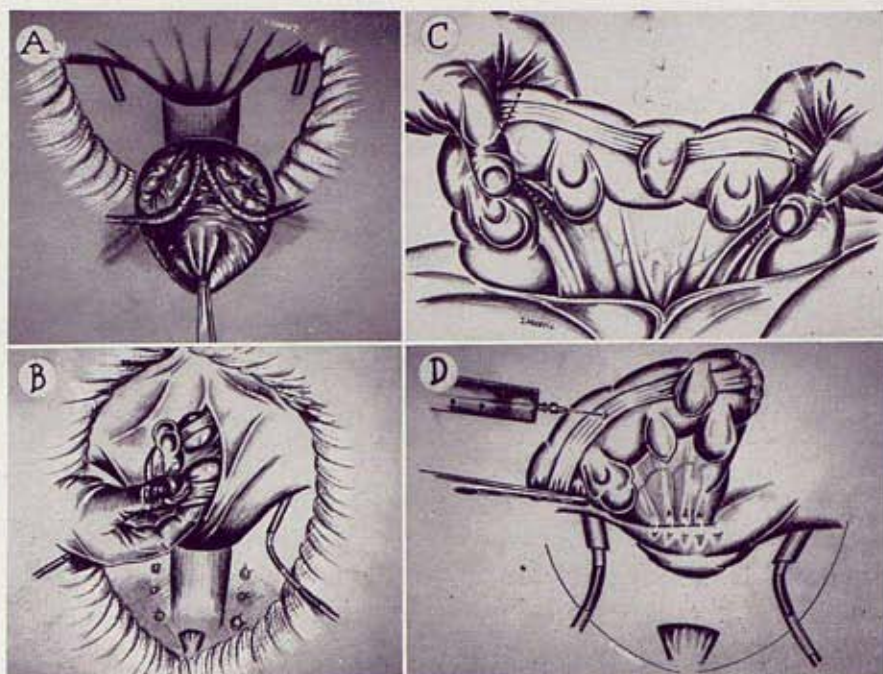


FIG. 4. A, total cysto-prostato-vesiculectomy. B, pulling out ileopelvic colon. C, dotted line shows section of intestinal segment. D, extraperitonealization of intestinal segment by suturing two serosal leaves of its meso to anterior parietal peritoneum.

eventuality it is essential, in the majority of cases, to lengthen the mesosigmoid, executed by transverse section of the serosa on both sides of the mesosigmoid (fig. 5). This technique has been described in a preceding publication<sup>3</sup> and with its possibilities, we have always been able to anastomose the intestinal segment to the urethra without undue tension. We know that the ileopelvic colon sometimes, due to some fecal stagnation, can enlarge up to a point where it can get to measure 25 to 30 cm. or even more; it is this fact that explains, according to Testut, the frequency of volvulus formation in this segment of the bowel both in the adult and in the aged.

Once the intestinal segment is isolated, the ends are closed, and a highly concentrated non-irritating bacteriostatic solution (chloramphenicol) is injected into it to avoid excessive mucus formation, which will render difficult the drainage of the intestinal segment in the immediate post-operative period, with possible formation of urinary fistulas; by this process we obtain bacteriologic cleansing of the intestinal segment (fig. 4, D).

<sup>3</sup> Gil Vernet, J. M.: Colo-cysto-plasties. *J. d'uro.*, 64: 301, 1958.

This stage is followed by closure of the peritoneal cavity with extraperitonealization of the intestinal segment; this is one of the most important operative stages, for intraperitoneal rough surfaces or areas should never be left, if we want to avoid postoperative intestinal obstruction. All the mesosigmoid of the intestinal segment without its serosa must be completely extraperitonealized. For this reason we have to be careful to close the anterior parietal peritoneum around it (fig. 4, D), that is, from the cul-de-sac of Douglas to the descending colon. In this way, the meso of the intestinal segment will be free, mobile and completely extraperitoneal; on the other hand, the abdominal cavity is completely closed and isolated from the pelvic excavation.

C) *Ureterosigmoid anastomosis.* The technique to be followed depends of any one's personal choice. If the ureter has been cut near the bladder, the Nesbit technique can be used, although we personally prefer the anastomosis in "trunk of an elephant" (fig. 11, F). If we are dealing with diffuse papillomatosis and the outlet of one or of the two ureters is far away from the tumor, we prefer to free the ureter with all its intramural



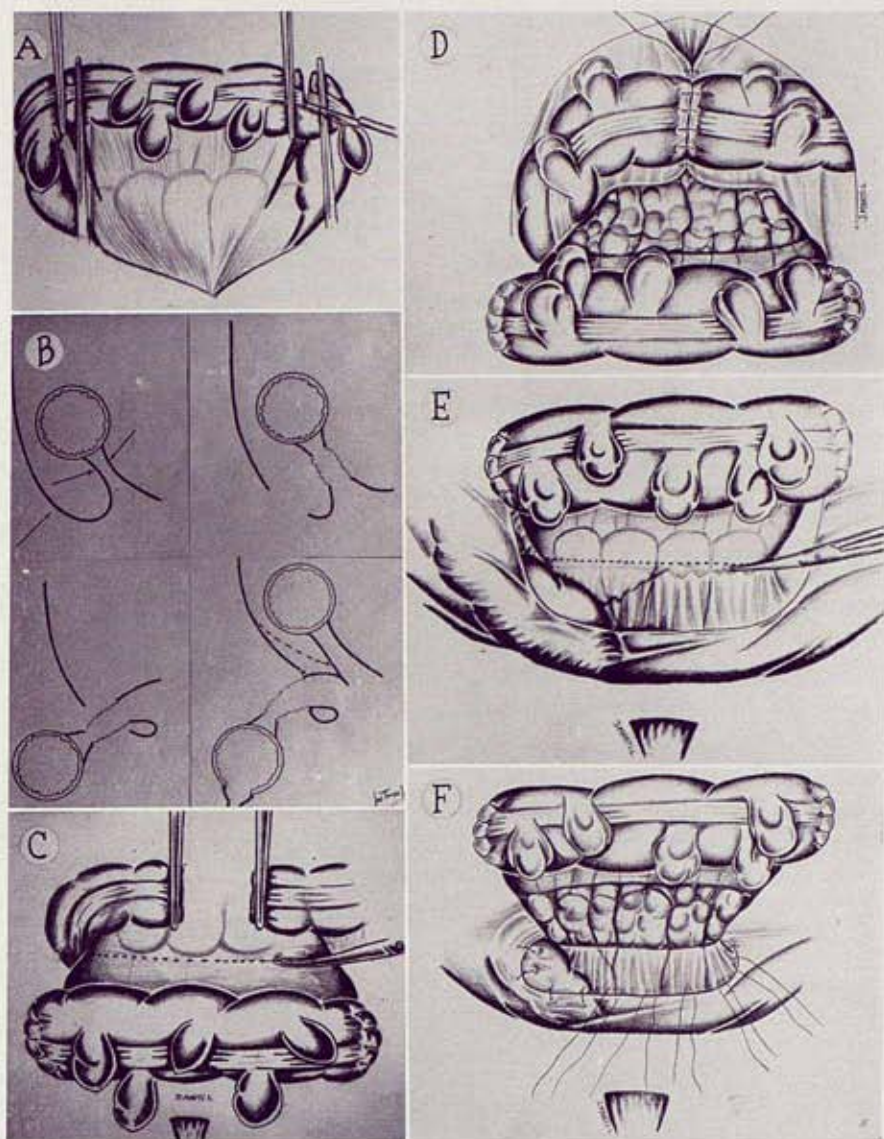


FIG. 5. A, obtaining intestinal segment. B, schematic drawing shows enlargement maneuver of mesosigmoid and extraperitonealization of intestinal segment. C, end-to-end anastomosis of colon from above meso of intestinal segment. Sectioning superior serosal leaf (enlargement maneuver). D, end-to-end anastomosis of colon completed and superior leaf incised. E, sectioning of inferior serosal leaf of intestinal segment at level of coalescence process and intersigmoid fossa. F, enlargement maneuver of mesosigmoid completed. Extraperitonealization of inferior surface.

portion, thus preserving the ureteral orifice together with a small portion of the mucosa around the ureteral meatus. This modification of the Bergenhem's technique<sup>4</sup> prevents stenosis of the ureterosigmoid anastomosis, and also

preserves normal ureteral peristalsis in its total integrity.

In order to perform ureterosigmoid anastomosis, a curved clamp is passed through the intestinal lumen, thus protruding on the *cintilla longitudinalis* in the selected place for the implant, in which case the left ureter will be very close to the proximal end of the intestinal segment; all the intestinal layers are incised, the

<sup>4</sup> Gil Vernet, J. M.: *Anatimofisiologia de los diferentes metodos de implantation uretero-intestinal Nuevas tecnicas. Cir. Ginec. y urol.*, vol. 3, 1952, page number not available.



forceps pulling the catheter until it appears in the lumen of the intestinal segment. The right ureter is anastomosed approximately in the mid-portion of the intestinal segment. After the anastomosis, the intestinal segment shows some degree of kinking (fig. 8, D) which can render difficult complete emptying of the newly formed bladder with this end-to-end technique.

D) *Urethrosigmoid anastomosis*. The end-to-

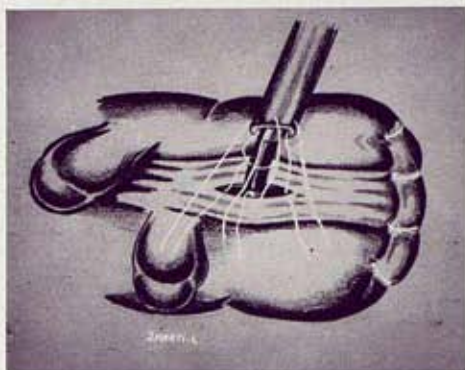


FIG. 6. Urethrosigmoidal anastomosis

end anastomosis between the urethra and the distal end of the intestinal segment can present some difficulties because of the different calibers between them. In some cases it will be necessary to make a cuneiform resection of the intestinal end (fig. 6) which will diminish its caliber. The anastomosis will be performed in two layers with interrupted sutures of 0000 chromic catgut.

First, posterior layer: It will join the serosa of the intestinal segment with the prostatic or periurethral structures (fig. 7, C). The stitches will not be tied until all of them are placed.

Second, posterior layer: This one will join the urethral and intestinal ends by means of total and interrupted sutures (fig. 7, C).

After this last layer is completed, a urethral catheter is passed and the tips of the ureteral catheters are introduced into its lumen and pulled outside through the urethra; the urethral catheter is again reintroduced and left indwelling (fig. 8, A) in order to drain some of the mucus or urine from the intestinal segment if one or both of the ureteral catheters become obstructed. Following this stage the first anterior layer (fig. 8, A

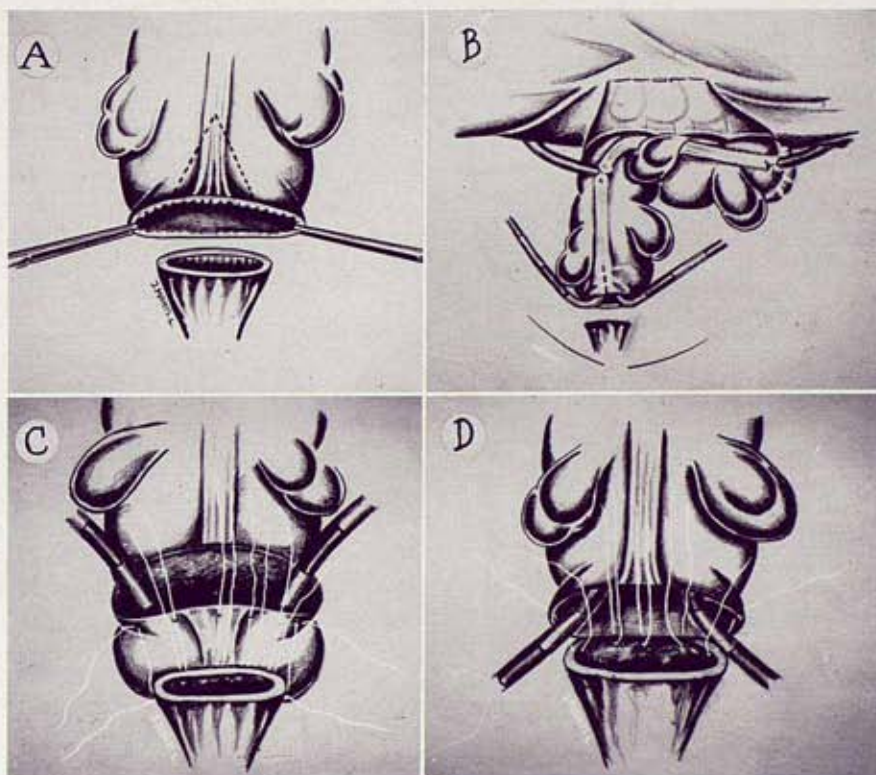


FIG. 7



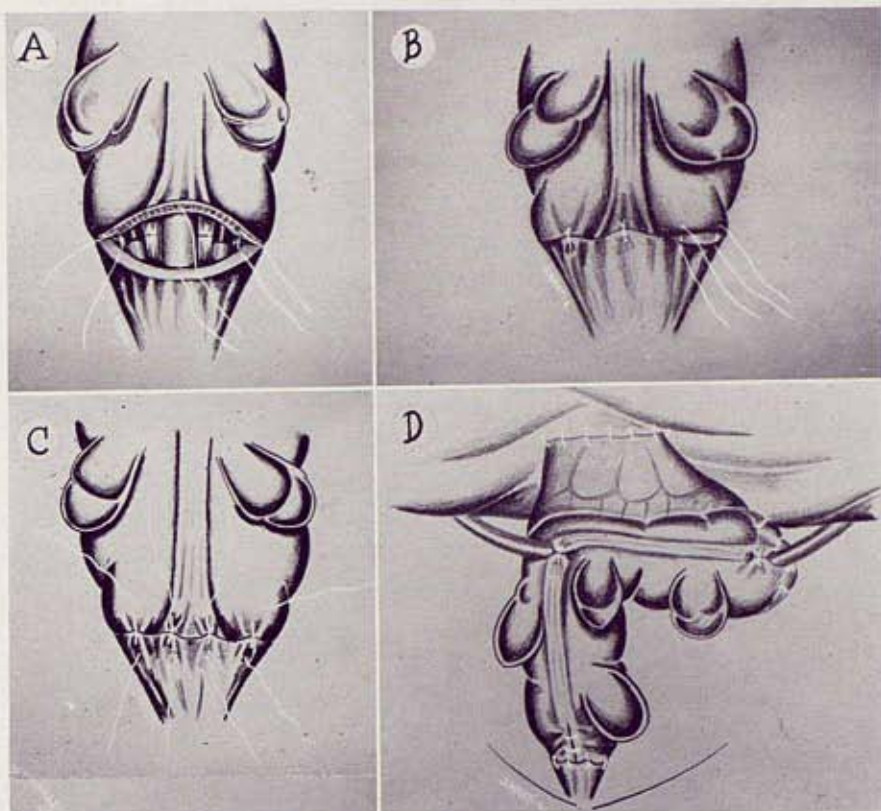


FIG. 8

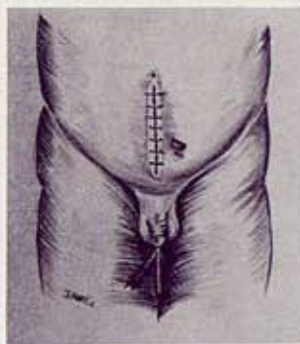


FIG. 9

and B), will be followed by the closure of the second anterior layer.

After all the anastomoses are finished, we proceed with irrigation and distention of the new bladder with a normal saline solution added of penicillin in order to verify the water-tight line of sutures.

Only one drainage tube is left in the retropubic space and exteriorized outside of the laparotomy wound (fig. 9).

The abdominal wall is closed in layers and with continuous wire sutures, because catgut sutures are not well tolerated by the traumatized edges of the laparotomy wound held for several hours under forceful tension by an autostatic retractor. The skin is closed with interrupted sutures of mane. All the catheters are secured and a forceful dilatation of the anus is done.

We do not consider it necessary to keep the colon at rest by a diversion colostomy.

#### TECHNIQUE NO. II (EXTRAPERITONEAL END-TO-SIDE ANASTOMOSIS)

The excision stage (isolation of the intestinal segment, extraperitonealization and transplantation of the ureters) is the same as for technique No. I, the only difference being in the end-to-side anastomosis between the urethra and the intestinal segment.

Once the intestinal segment is obtained, both ends are closed, and the bacteriostatic solution is injected into it (fig. 10, C).

In the midportion of the intestinal segment and



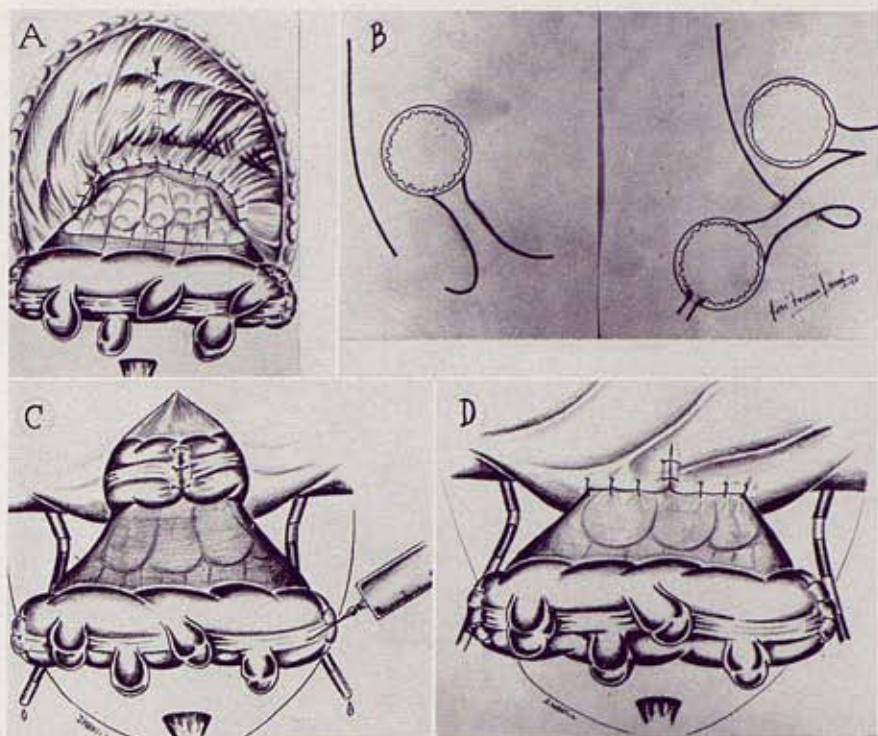


FIG. 10. A, suturing of anterior parietal peritoneum around meso of end-to-end anastomosis of colon. B, schematic drawing shows extraperitonealization of intestinal segment in cases of large meso where enlargement is not needed. C, large mesosigmoid which has no need for enlargement. D, suturing of anterior parietal peritoneum to serosal leaf of mesosigmoid which had no need for enlargement.

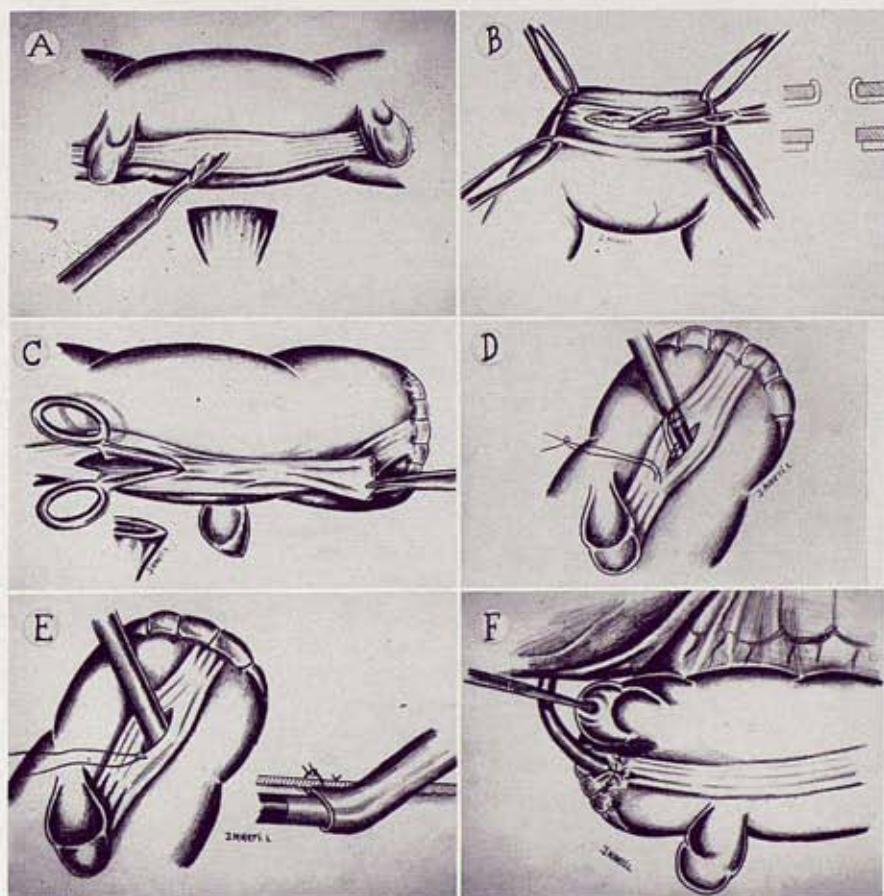


FIG. 11



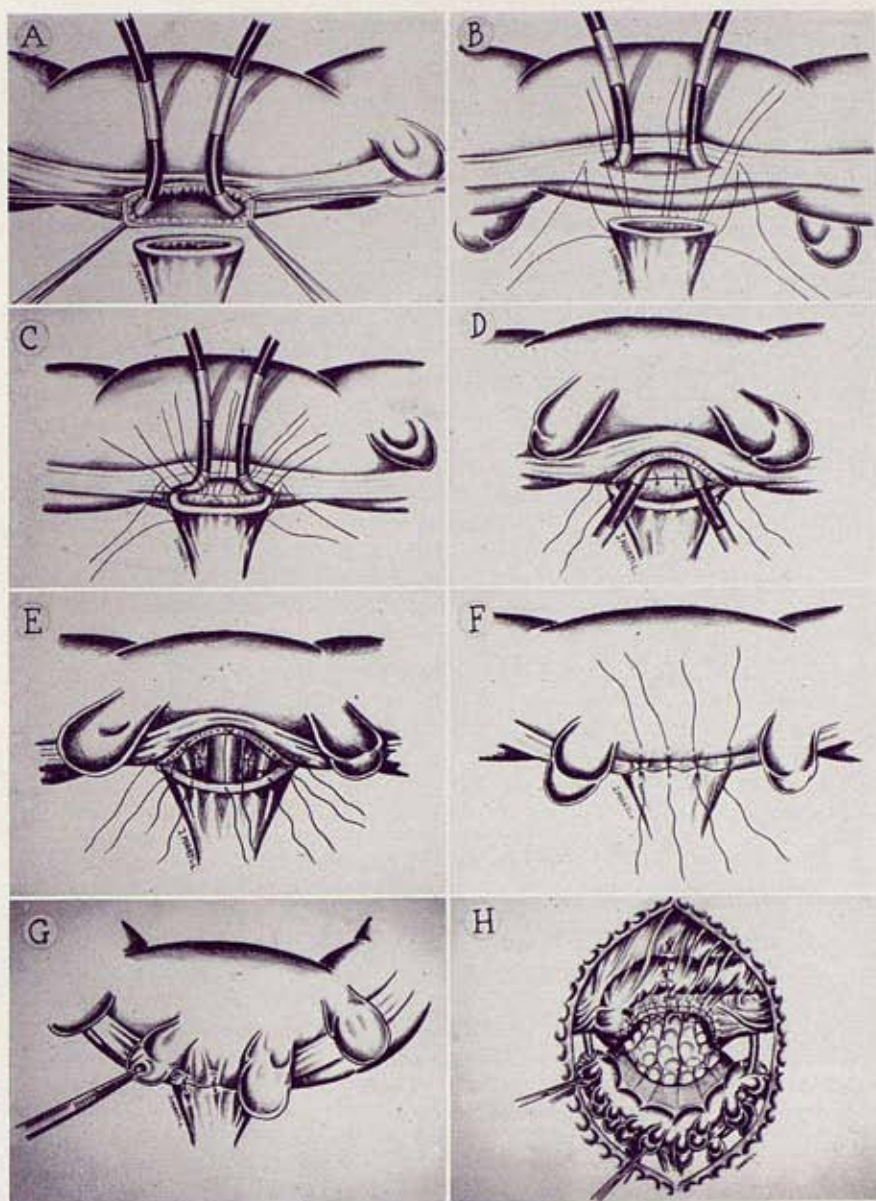


FIG. 12

on its antemesenteric edge, an incision of  $1\frac{1}{2}$  to 2 cm. in length is made; this will be the new intestinal ostium. To avoid extrusion of the intestinal mucosa (fig. 11, B) which could produce urinary fistulas, we proceed with resection of 2 cm. of the mucosa (fig. 11, B) that surrounds the intestinal ostium.

The curved clamp is introduced through the incision (fig. 11, C) and we proceed to transplantation of the ureters. Each one of the ureters

will be transplanted in the end zones of the intestinal segment.

The side-to-end anastomosis of the urethra and of the intestinal segment will be done in two layers (fig. 12).

Once the operation is completed, the new bladder will show a U shaped curve without any kinking. Technique No. II is more laborious and more complex than No. I but the postoperative results are likely to simulate a normal bladder and



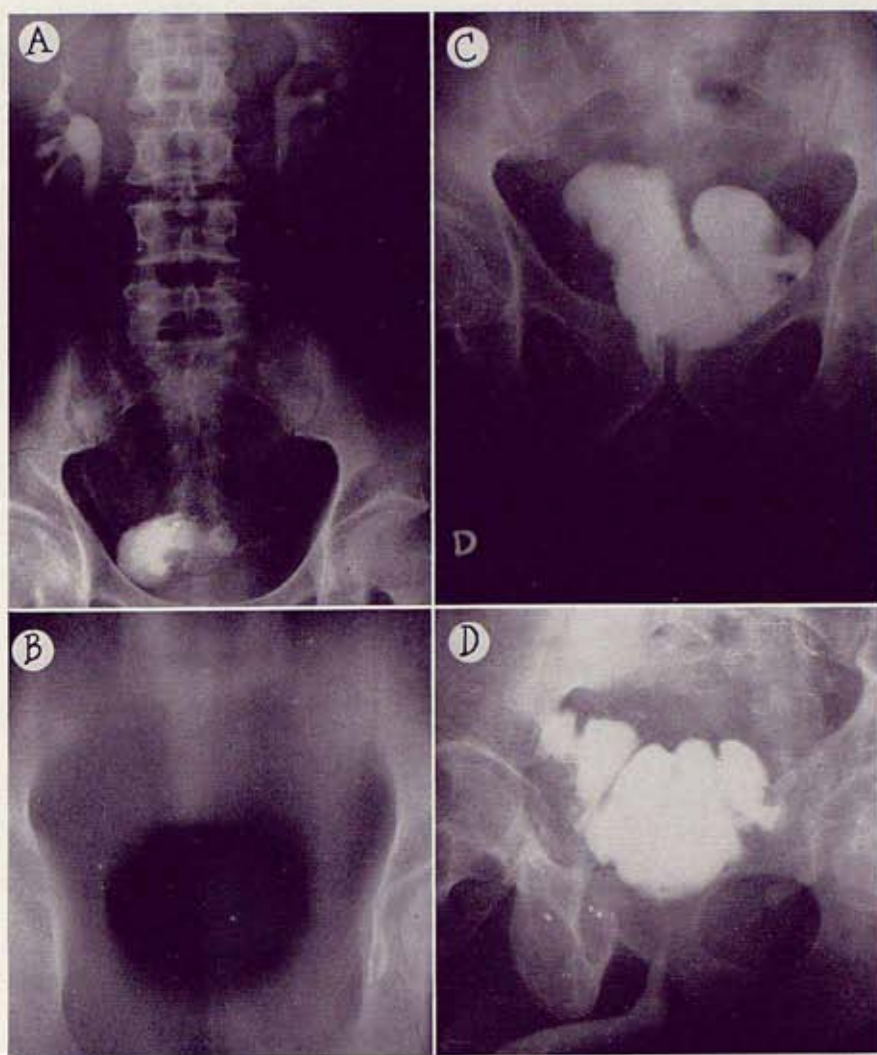


FIG. 13. Case 11. Technique No. II (end-to-side). Anastomosis of intestinal segment to membranous urethra. *A*, preoperative excretory urogram. Note vesical filling defect. *B*, vesical planigraphy. Infiltrating tumor of left lateral wall. *C*, oblique urethroecystogram (3 months after operation). *D*, retrograde cystogram 30 days after operation, in full stage of accommodation.

the course of the ureters is maintained in a normal position. Functionally, the results also appear superior to those obtained by technique No. I. (Figs. 13-15 are from a case that was operated upon by this last technique.)

A Wangenstein drainage tube is maintained during the first two or three days. The newly formed bladder is irrigated three times daily with a normal saline solution and so are the ureteral catheters as well; these will be removed on the sixth or seventh postoperative day, thus enabling the patient to get out of bed. Forty eight hours

after operation, a laxative is prescribed to liquify the feces and to permit their passage through the colonic anastomosis. The urethral catheter will be removed on the tenth or twelfth postoperative day, and the patient discharged. Antibiotics and chemotherapeutic drugs are given periodically for the first few months depending on the bacterial flora of the newly formed bladder which is generally made up of *B. proteus*, which does not seem to have any pathological influence even though it is present for a long time.



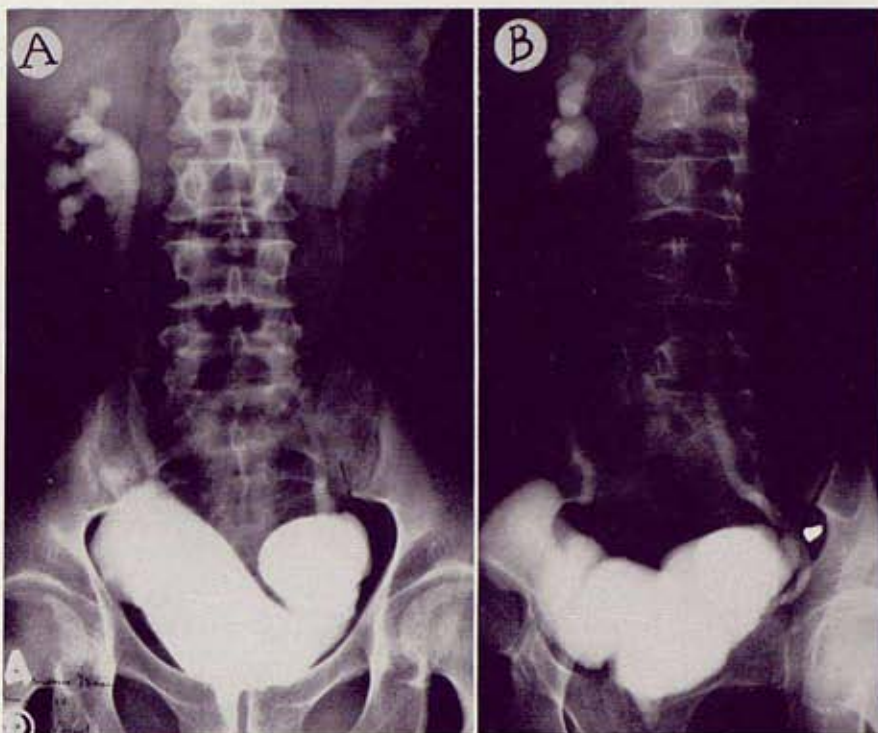


FIG. 14. Case 11. *A*, excretory urogram combined with retrograde cystogram (1 year after operation). Slight ureteral reflux on right side after maximum distention of "new bladder." *B*, excretory urogram with patient in oblique position (1 year after operation).

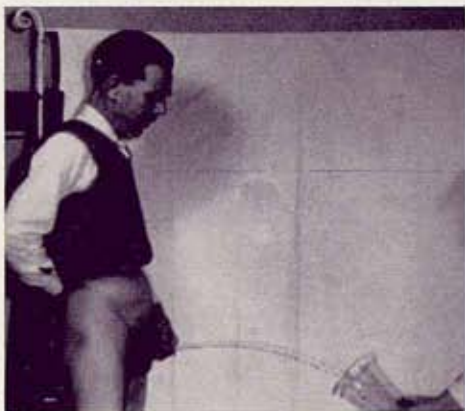

FIG. 15. Case 11. Patient during micturition (1 year following operation). Perfect diurnal and nocturnal continence; voiding every 4 to 5 hours.

The mucus formation from the intestinal segment is practically not seen while the bladder is "dry" but once the new bladder gets to function, there is an increased amount of mucus due to the irritative action of the urine; however the mucus formation is at a much lesser degree than

when the ileum is used and as the time goes by, there is a remarkable decrease of it.

#### TOLERANCE AND OPERATIVE TIME

In spite of the length of time that it takes for the operation, which is performed upon patients with malignant tumors in poor general condition, some of them being reoperated on in ages varying between 60 to 75 years of age, all have tolerated the procedure well and none have shown symptoms of shock.

The average operative time was 3½ hours.

#### COMPLICATIONS

Having in mind that we are working on a cancerous patient, the possibility of complications is logically greater than with colo-cystoplasty for a small tuberculous bladder.

The complications encountered in a total of 15 operative cases were:

Urinary fistulas: 4 cases, located at site of the urethrosigmoid anastomosis. They were reoperated upon and recovery was uneventful. The



other cases healed just by leaving an indwelling urethral catheter for as long as 20-25 days.

Intestinal complications: 1 case of intestinal obstruction because of a peritonealization defect.

#### MORTALITY

Among the total number of 15 cases there have been 3 deaths: 2 patients died on the fourth and on the eighth postoperative day respectively, because of myocardial damage after good tolerance of the surgical intervention; the third died from intestinal obstruction due to a technical defect in the extraperitonealization process; in fact in this case, surgical intervention was

extremely laborious because of scar tissue and the patient's obesity (110 kg.). The patient was re-operated upon but he died.

The results obtained in all other cases are really satisfactory and hopeful and will be the subject of a detailed revision in a forthcoming publication.

#### SUMMARY

An entirely new operative technique for construction of a functioning artificial bladder has been used in a small series of 15 patients. Indications for and techniques of the operation have been discussed.