

TRANSLUMBAR SPLENECTOMY IN HUMAN KIDNEY TRANSPLANT RECIPIENTS

H. VAN POPPEL, J. M. GIL-VERNET, A. CARALPS AND C. FERNANDEZ, JR.

From the Catedra de Urologia, Faculty of Medicine, University of Barcelona, Barcelona, Spain

ABSTRACT

A simple technique of translumbar splenectomy during renal and pancreatic transplantation is described. This unique approach was used in 18 patients. Postoperative septic complications must be considered.

The procedure was done in 11 male and 7 female patients between 13 and 55 years old. There were 14 cases of orthotopic renal transplantation, and 4 lumbar pancreatic and lumboiliac kidney insertions from 10 living related and 8 cadaver donors.

METHOD

For more than 5 years we have used the splenic vessels in renal and pancreatic transplantation.¹ In cases of classical orthotopic renal or lumbar pancreatic transplantation the recipient renal vein, splenic artery and entire urinary excretory system for pyelo-pyelic (fig. 1) or Wirsung's duct-pyelic anastomosis are used.²

The patient is placed in a dorsolateral position with a pillow under the costal rim. Through a left posterolateral lumbotomy the 12th rib is resected completely (fig. 2). A nephrectomy is performed, preserving the integrity of the renal vein and pelvis. Gentle downward pulling on the adrenal gland, separating it from the anterointernal adhesences,³ exposes the splenic vascular bundle through the upper part of the parietal posterior peritoneum (fig. 3, A). The splenic artery is isolated and divided at the level of bifurcation after incision of the parietal peritoneum and Treitz fascia. Relief of the spleen is appreciated more laterally (fig. 3, B). An incision of the covering peritoneal layer is performed and enlarged, enabling exposure and dislocation of the spleen from the peritoneum into the retroperitoneal space (fig. 4, A). The arteries and veins of the spleen are tied and severed close to it, far from the pancreas and stomach (fig. 4, B). After hemostasis is examined the peritoneal incision is closed with a running suture (fig. 4, C).

RESULTS

The operative exposure mediating this approach is excellent. No technical problems were encountered in the performance of the splenectomy. Ligation of the splenic and short gastric vessels, and peritoneal closure were easy in all cases. No perioperative or postoperative bleeding, and no pancreatic or gastric damage occurred. No prolonged paralytic ileus was encountered. In 2 patients septicemia developed owing to bronchopneumonia, and one died of a cytomegaloviral infection postoperatively.

DISCUSSION

The immunological benefit of splenectomy in renal transplantation is still controversial, although some authors recommend splenectomy in all recipients of mismatched kidneys.⁴ Splenectomy before or after renal transplantation or simultaneous transperitoneal removal of the spleen during a retroperitoneal kidney graft insertion increases the immediate morbidity and the number of operations for the patient.⁵ With our method of splenectomy these disadvantages are avoided. Others also mention the superiority of loin incisions for difficult sple-

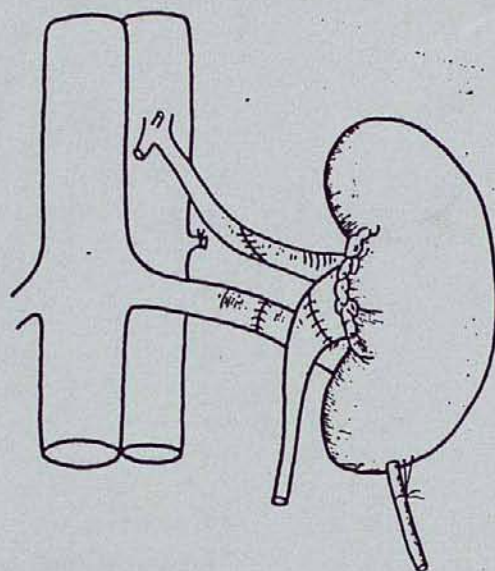


FIG. 1. Schematic representation of classical orthotopic renal transplantation with splenorenal arterial, reno-renal venous and pyelo-pyelic anastomosis, and nephrostomy tube.

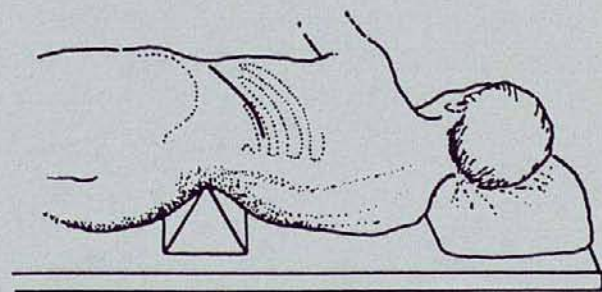


FIG. 2. Position of patient and posterolateral lumbotomy incision

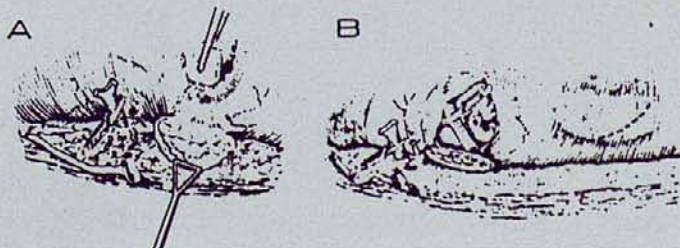


FIG. 3. A, exposure of splenic vessels through parietal peritoneum after preparation of renal vein and pelvis, and ligation of renal artery. B, lateral peritoneal incision.




FIG. 4. A, exposure of spleen. B, dislocation of spleen and ligation of vessels. C, closure of parietal peritoneum

nectomy.⁶ Ligation of the splenic artery for subsequent kidney or pancreatic arterial reconstruction surely facilitates removal of a spleen that frequently is enlarged in patients undergoing chronic hemodialysis.

Previously reported complications of splenectomy include long-term risk of sepsis, wound infection, operative death,⁵ death owing to overwhelming bacterial infection⁷ and thromboembolic problems.⁸ We cannot make any statement about those complications, although some degree of predisposition to sepsis is suspected.

We conclude that 1) the technical performance of splenectomy mediating a posterolateral lumbotomy is a safe procedure, 2) splenectomy performed during orthotopic renal transplantation does not aggravate the intervention and 3) the incidence of septic complications could be higher in the postoperative period. When splenectomy is necessary, the translumbar approach is a simple technique, especially when orthotopic renal or lumbar pancreatic transplantation is contemplated.

REFERENCES

1. Gil-Vernet, J. M.: *Cirurgia del trasplante renal*. In: *Trasplante Renal*. Edited by A. Caralps and J. M. Gil-Vernet. Barcelona: Toray S. A., chapt. 18, pp. 175-191, 1983.
2. Gil-Vernet, J. M. and Caralps, A.: *Transplantation rénale orthotopique*. *Sém. Urol. Néphrol.*, 10: 23, 1984.
3. Gil-Vernet, J. M., Caralps, A. and Ruano, D.: *New approach to the splenic vessels*. *J. Urol.*, 119: 313, 1978.
4. Fryd, D. S., Sutherland, D. E. R., Simmons, R. L., Ferguson, R. M., Kjellstrand, C. M. and Najarian, J. S.: *Results of a prospective randomized study on the effect of splenectomy versus no splenectomy in renal transplant patients*. *Transplant. Proc.*, 13: 48, 1981.
5. Matas, A. J., Simmons, R. L., Buselmeier, T. J., Najarian, J. S. and Kjellstrand, C. M.: *Lethal complications of bilateral nephrectomy and splenectomy in hemodialyzed patients*. *Amer. J. Surg.*, 129: 616, 1975.
6. Turner-Warwick, R. T.: *The supracostal approach to the renal area*. *Brit. J. Urol.*, 37: 671, 1965.
7. Krivit, W., Giebink, G. S. and Leonard, A.: *Overwhelming post-splenectomy infection*. *Surg. Clin. N. Amer.*, 59: 223, 1979.
8. Bennett, W. M., Boileau, M., Barry, J. M., Lawson, R. K. and Hodges, C. V.: *Role of splenectomy in renal transplantation*. *Urology*, 2: 542, 1973.

EDITORIAL COMMENT

The authors have demonstrated that splenectomy may be performed through the left retroperitoneal space in conjunction with renal transplantation into the native renal bed. However, the advisability of this procedure is open to question in at least 3 areas. 1) The occurrence of sepsis following splenectomy is recognized in the population at large and is likely to be even greater in the immunosuppressed renal transplant patient. Generalized improvements in renal transplant graft survival owing to improved immunosuppression, primarily with cyclosporin, and improved histocompatibility matching accompanied by steadily decreasing patient morbidity lessen the need for the putative immunological benefits of splenectomy. 2) Renal transplantation itself into the native renal bed seems likely to increase the difficulty of the vascular anastomoses. Pyeloureterostomy remains an excellent method of repairing injuries to the transplant ureter but it is associated with a higher complication rate than transplant ureteroneocystostomy as the primary procedure.

Arthur I. Sagalowsky
Department of Urology
University of Texas
Dallas, Texas

REPLY BY AUTHORS

1) To decrease the postoperative morbidity and mortality by septic complications we suggest preventive antibiotic therapy and streptococcal vaccination. 2) The desirability of splenectomy in renal transplantation still is a matter of discussion. It was not the aim of this article to evaluate its immunosuppressive effect. 3) In our hands the posterior lumbar approach for vascular anastomoses using the splenic vessels was excellent for easy reconstruction in all cases and our pyelo-pyelic anastomoses resulted in a negligible complication rate. The results of our first orthotopic renal transplantations have been published previously (reference 2 in article).