

TRANSVERSE URETEROTOMY

JOSÉ M. GIL-VERNET

Longitudinal ureterolithotomy has been a dogma in urology as was longitudinal pyelotomy. The latter procedure has been surpassed and the former is undergoing the same fate, which is fortunate because of its uncertain consequences.

Complications that can result from a longitudinal ureteral incision are well known. Frequently, when large or embedded calculi are extracted the incision will tear and be difficult to suture. Even when suitable material is available, the stitches will tear the lips of the wound or noticeably reduce the diameter of the ureter, resulting in temporary or persistent outflow of urine. However, even if the wound is not torn its closure will cause a certain degree of stenosis. This stenosis occurs mainly at the level of the stone's ureteral bed at which place the stone, because of its irritating presence, has caused all layers of the ureter to thicken and possibly caused inflammatory hyperplasia of the mucous membrane (fig. 1). Because of these problems with the longitudinal incision there has been much controversy of whether the wound should be sutured after lithotomy. However, if not closed outflow of urine occurs frequently with possible sequelae, sometimes with the formation of fistulas that may lead to loss of the kidney. In the best case this temporary outflow of urine causes sclerosis of the adventitia and the periureteral cellular tissue which may compress the ureter, thereby endangering its physiology.

An ideal ureteral incision would 1) avoid extravasation of urine, fistulas and stenosis; 2) facilitate extraction of calculi; 3) make possible a watertight closure, easy for the surgeon to perform and 4) not alter the opening of the ureter nor its dynamics.

Results of our experimental research revealed that the transverse ureterotomy met these requirements. An incomplete incision in a ureter, involving two-thirds or half of its circumference but followed by a meticulous closure, does not obstruct the alignment between the segments overlying and underlying the incision nor give rise to immediate or distant alterations in the ureteropyelic tonicity. In addition, a transverse ureteral incision offers greater resistance to tearing than a longitudinal incision.

The nature of the pyeloureteral physiology was studied by cine-urography and urograms taken in a series. Physiology was not even altered immediately following partial section of the ureter in situ because the parietal continuity is maintained, making it possible for the peristaltic waves

to be transmitted without interruption, even through several stepped transverse incisions. Also in unblocking arterial vessels, except for the aorta, the transverse arteriotomy is preferred over the longitudinal incision since it prevents reduction of the vessel's diameter. In accordance with physical laws only half of the tension that a longitudinal suture has to withstand is present with a transverse suture.

Based on these experimental studies, the first transverse ureterolithotomy was done on man in 1969. We have now performed 73 operations with satisfactory results. In 2 patients 3 incisions were made in the same ureter at different heights. The incision has never involved more than two-thirds of the ureter's circumference while, generally, it only involves half or a third of its circumference. Fistulas have not been noted in 72 of the 73 cases nor has outflow of urine through the drainage tube. In 19 cases all types of drainage were dispensed with and convalescence was uneventful.

A catheter was placed in 1 patient for 15 days for a fistula in the juxtavesical ureterotomy and the patient was cured. This complication, which has been observed in 1 case only, suggests that the transverse incision should not be used in the last 2 cm. of the ureter because the circulation is practically terminal in this section.

Most patients were discharged from the hospital after 4 or 5 days and, except for the patient with the temporary fistula, none was hospitalized for more than 7 days. Distant radiographic check has made it possible to confirm the absence of stenosis at the level of the incision and the perfect peristaltic transmission of the overlying and underlying segments.

TECHNIQUE

Once the ureter containing the calculus has been identified, a 3 cm. incision is made in its sliding sheath. Babcock clamps are placed above and below the calculus, thereby fixing the ureter with its calculus in situ. The depth of the field permitting, we use 2x lenses by means of which a greater accuracy in the operating procedure is achieved. At the upper third of the calculus a transverse incision is made with a thin scalpel; the cut must be perpendicular to the ureter wall. The calculus is detached with a thin, microsurgical spatula and by tilting the Babcock clamps the calculus comes out of the ureter. The permeability of the duct is checked, the former bed of the stone is normalized if necessary and suturing is done with a fine atraumatic cylindrical needle and 6 or 7-zero chromic catgut. The needle is inserted 2 mm. from

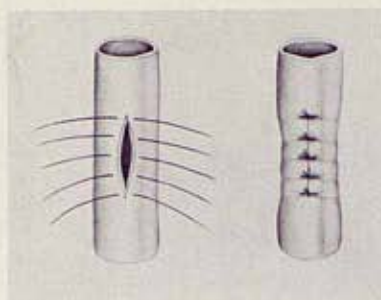


FIG. 1. Closure of longitudinal ureteral incision results in some stenosis.

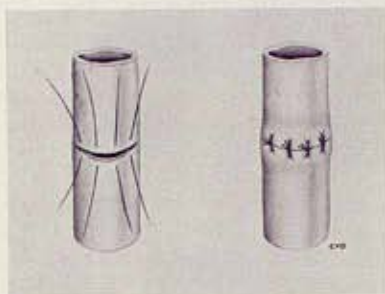


FIG. 2. Closure of transverse ureteral incision avoids stenosis and allows secure re-establishment of lumen and of ureteral physiology.

the edge of the wound and should penetrate all layers except the mucous membrane, which should be carefully kept from everting. The distance between stitches is 2 to 3 mm. If a stitch is perforated, it is of no great importance. The knots

should not be excessively tightened but closure must be watertight. If the incision involves three-fourths of the ureter's circumference, the suture may be continuous with it being fundamental that the suture be meticulous and, in particular, that the needle be appropriate for the catgut which should by no means be less than 6-zero. If possible the ureter should be restored to its sliding sheath.

When performed under these conditions the transverse ureterotomy does not cause stenosis (fig. 2) and is easier and safer to close because it offers greater resistance to tearing than the longitudinal incision. A surgical microscope or magnifying glass can be useful in the visceral stage of the extraction of a ureteral calculus that has been embedded for a long time. Postoperative drainage is not necessary if the surgeon maintains an absolute check on the operation and the urine is not infected.

SUMMARY

Because of complications that may occur with a longitudinal incision for ureteral stones, a transverse incision has been studied. Experimental studies proved that the direction of the incision was important from the urodynamic viewpoint. The transverse incision does not reduce the ureteral caliber and does not deteriorate its pyeloureteral physiology, not even in the cases in which partial section of the ureter involves half to two-thirds of its circumference. This incision allows a safe and perfect re-establishment of the ureteral opening.

Catedra de Urologia, Facultad de Medicina, Universidad de Barcelona, Casanova 143, Barcelona 11, Spain