

## UROGENITAL DIAPHRAGM RAISING MANEUVER

J. M. GIL-VERNET, R. GUTIERREZ DEL POZO, P. CARRETERO, J. A. CAMPOS AND  
J. M. GIL-VERNET, JR.

From the Hospital Clinic I Provincial, Urology Department, University of Barcelona, Barcelona, Spain

### ABSTRACT

The urogenital diaphragm raising maneuver, a procedure to facilitate membranous urethral surgery, is described. The technique shortens operating time by permitting easy identification and exposure of the severed urethral ends, thus, allowing for precise re-establishment of urinary tract continuity. Selective membranous urethral surgery can be performed with ease, preserving external sphincter integrity. This maneuver represents an advance over any other technique by almost eliminating the risk of stenosis, urinary fistula and incontinence owing to failure of precise reapproximation of the membranous urethra. (*J. Urol.*, 140: 555-558, 1988)

We describe a maneuver that greatly simplifies surgery of the membranous urethra by raising the urogenital diaphragm. This is difficult owing to the depth of the operative field and friability of the tissue, which do not lend to anatomical repair. The usefulness of this maneuver has been shown in practice to solve problems observed in different situations, such as in cases of membranous urethral trauma, prostatic cancer surgery and intestinal bladder substitution procedures. All of these procedures have a difficult step, namely the re-establishment of urethral continuity by anastomosis to the membranous urethra. Some investigators have mentioned correctly that the voiding future of the patient depends on perfect execution of this step in the procedure.

Re-establishment of lower urinary tract continuity when the membranous urethra is severed is a major surgical problem owing to the almost unrecognizable blunted urethral fragments, particularly at the distal portion, which is retracted below the medial perineal aponeurosis (fig. 1, A). Also, the pelvioperineal hematoma secondary to trauma makes tissue identification difficult, thus, causing difficulty in dissection of a deficient

membranous urethra as well as identification of the external urethral sphincter.

The exposure and presentation that allow for easy and adequate end-to-end anastomosis of the urethra to the bladder after radical prostatectomy or to an isolated intestinal segment after radical cystectomy also present a problem. Undoubtedly, the anatomical and functional result of this operation depends on the quality of this anastomosis, and to date no surgical technique offers adequate exposure.

### MATERIALS AND METHODS

The maneuver presented is simple and consists of retrograde urethral catheterization up to the surgical cavity, where an end-to-end suture is placed between 2 Foley catheters that are not greater than 16F (fig. 1, B). The urethral catheter is pulled distally until the Foley balloon of the abdominal catheter is at the bulbar position. Fluid (3 to 5 ml.) is injected into the balloon (fig. 1, C) and the 16F catheter is pulled cranially towards the surgeon (fig. 2, A).

The traction offered by the catheter raises the urogenital diaphragm and produces eversion of the membranous urethra.

Accepted for publication December 21, 1987.

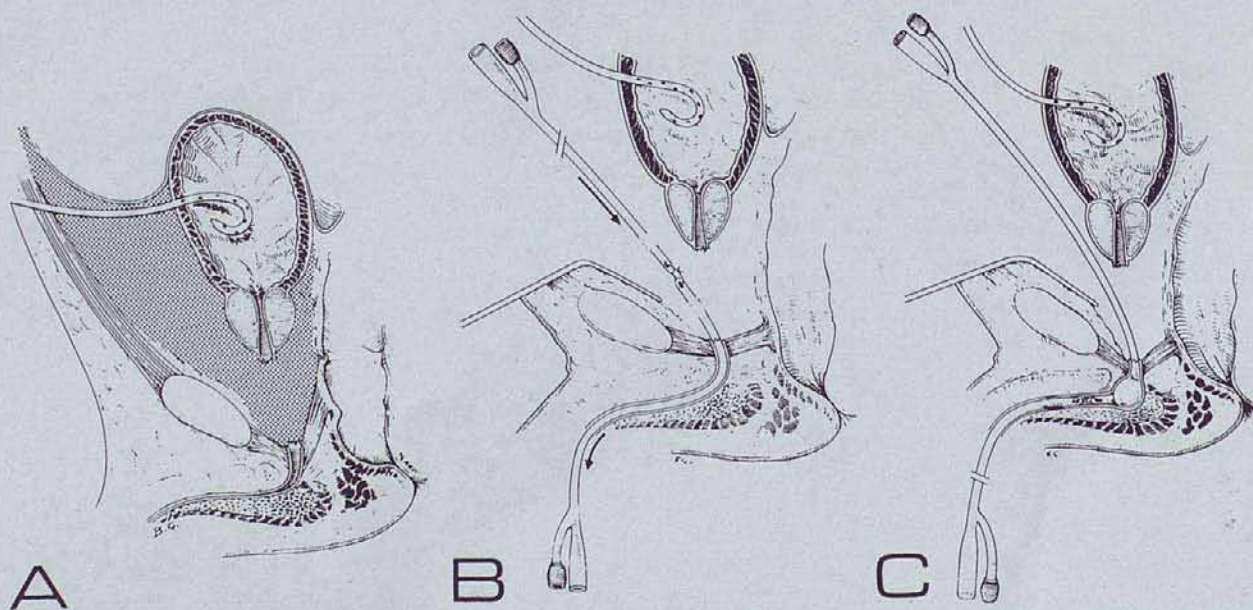


FIG. 1. A, pelvioperineal hematoma and blunted, retracted urethral fragments. B, catheter alignment. C, balloon inflated at bulbar portion. Catheter is not greater than 16F.

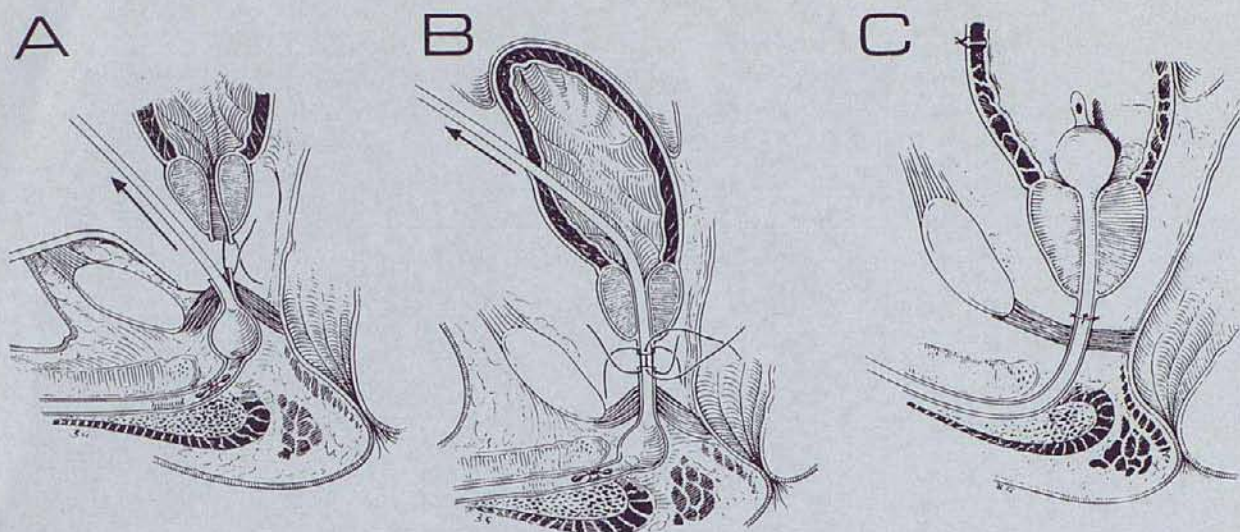


FIG. 2. *A*, upward traction and first suture at posterior edge. *B*, completing anastomosis. *C*, selective urethral anastomosis is finished

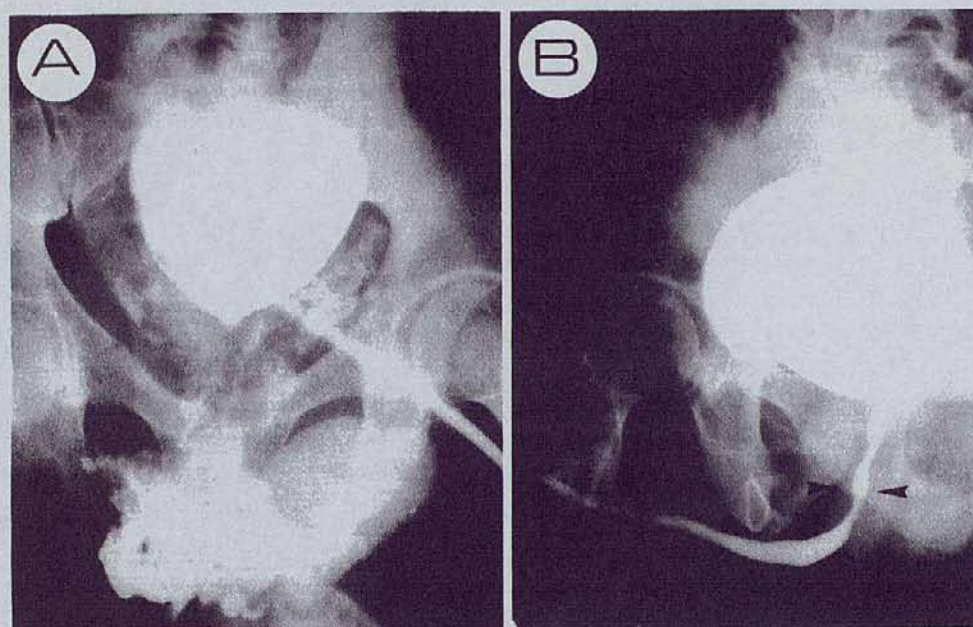


FIG. 3. *A*, cystography through suprapubic stent shows upward bladder displacement and medium extravasation. *B*, cystourethrography 1 year later reveals excellent results and urinary continence. Arrowheads show anastomotic site.

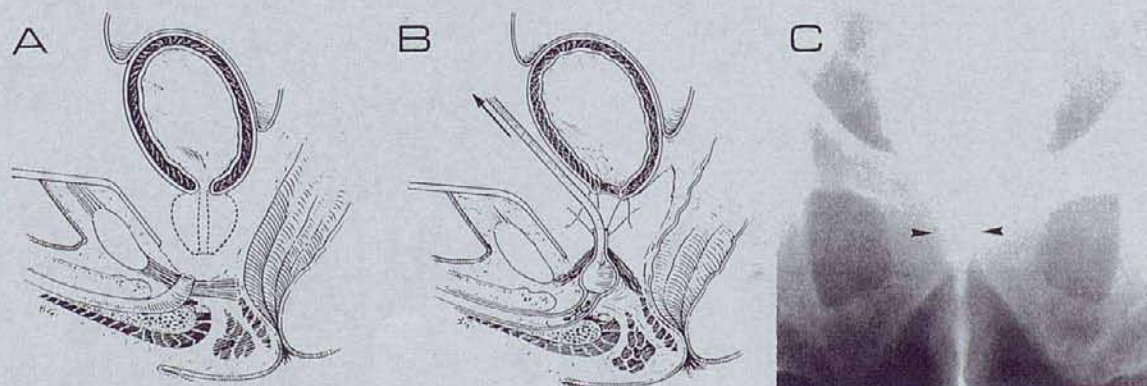


FIG. 4. *A*, radical prostatectomy. *B*, re-establishment of urinary continuity through raising maneuver. *C*, voiding cystourethrography 1 year after radical prostatectomy. Arrowheads show anastomosis.

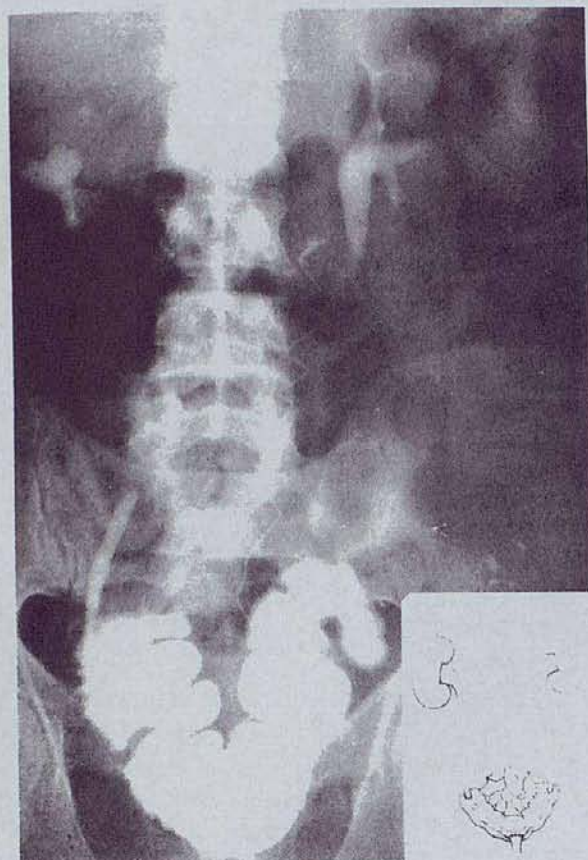


FIG. 5. Excretory urogram shows sigmoid substitution of bladder

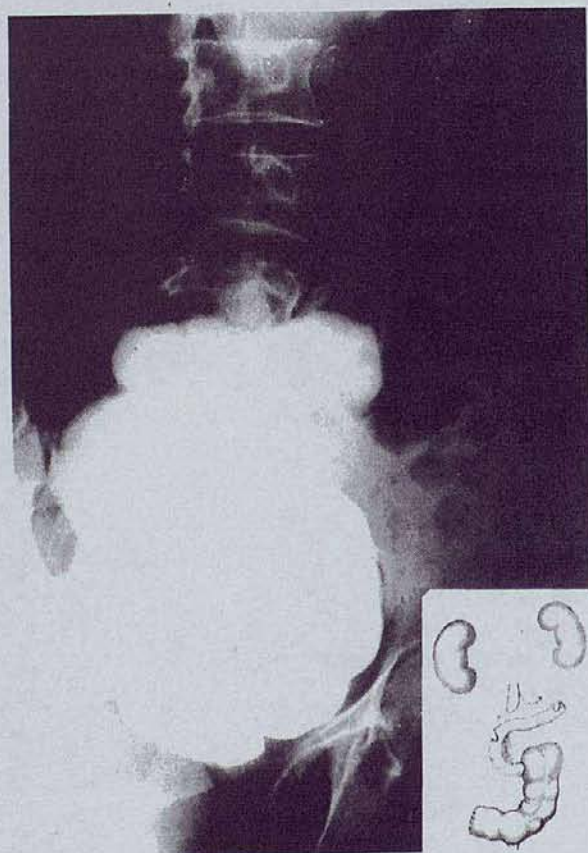

FIG. 6. Cystography demonstrates ileocolic bladder substitution

#### Preliminary results

	No. Cases	Fistula	Incontinence	Stenosis
Urethral trauma	4	0	0	0
Radical prostatectomy	16	0	0	0
Intestinal bladder substitution	4	0	4*	0

\* Nocturnal incontinence only.

The maneuver elevates the membranous urethra and pelvic diaphragm by almost 15 mm., which allows for visualization of tissue sliding from the surrounding external sphincter (fig. 2, B). Visualization of the membranous urethra and opacification of that structure from the external sphincter are fundamental because should the sutures include the external sphincter musculature urinary incontinence is likely. Single 5-zero catgut sutures are placed as with a vascular anastomosis. The distance between the sutures is not less than 3 mm. (fig. 2, C).

Good exposure of the distal stump of the urethra helps in the event of sectioning to enable the surgeon to recognize the torn and ischemic fragments. This permits precise removal of devitalized tissue and careful reapproximation (fig. 3).

Radical prostatectomy (fig. 4, A) essentially is a difficult surgical technique<sup>1</sup> and urethral reapproximation is the most problematic part of the operation. Incontinence, fistulas and strictures are common, and they are the main reasons why surgeons are not enthusiastic about radical surgery, which remains the best treatment for localized prostatic cancer.<sup>2</sup> During radical prostatectomy, the maneuver described is of great help in the reanastomosis of the urethra. The risk of stenosis and fistulas is minimized by perfect tissue apposition without tension (fig. 4, B and C), as well as in cases of intestinal segment substitution (figs. 5 and 6).<sup>3-5</sup>

#### RESULTS AND DISCUSSION

We have performed this technique in 24 patients since March 1986 (see table). Of these patients 4 had a severed urethra secondary to pelvic fracture and 16 underwent radical prostatectomy secondary to prostatic carcinoma. In 3 of the latter patients partial incontinence was observed during the first 2 months postoperatively, which disappeared progressively after a sphincter re-education program. No other major complication has been observed. In the remaining 4 patients in whom bladder substitution was done good diurnal continence and persistent nocturnal incontinence were still observed, as frequently occurs in these cases. The number of patients studied is small since we began to use this maneuver but it does demonstrate encouraging results.

Selective suturing of the urethra without skeletal muscle fiber inclusion serves to preserve urinary continence. By introducing this maneuver, radical surgery of the prostate is less complex. With the decrease in morbidity the attitude of the urological surgeon will change when faced with this frequent pathological condition.

#### REFERENCES

1. Léandri, P. and Rossignol, G.: La cystectomie totale pour cancer: technique chirurgicale, morbidité post-opératoire et, résultats fonctionnels. *Cahier Chirurg.*, **59**: 9, 1986.
2. Benson, R. C., Jr., Tomera, K. M., Zincke, H., Fleming, T. R. and Utz, D. C.: Bilateral pelvic lymphadenectomy and radical retro-pubic prostatectomy for adenocarcinoma confined to the prostate. *J. Urol.*, **131**: 1103, 1984.
3. Gil-Vernet, J. M., Escarpenter, J. M., Perez-Trujillo, G. and Vic, J. B.: A functioning artificial bladder: results of 41 consecutive cases. *J. Urol.*, **87**: 825, 1962.
4. Gil-Vernet, S., Gil-Vernet, J. M., Jr., Vic, J. B. and Escarpenter, J. M.: Functional results of an artificial bladder. Section II. *J.*

- Urol., **87**: 837, 1962.  
5. Gil-Vernet, J. M., Jr.: The ileocolic segment in urologic surgery. *J. Urol.*, **94**: 418, 1965.

retropubic prostatectomy. Urologists' Correspondence Club, January 8, 1986.

#### EDITORIAL COMMENT

This technique to identify the urethra also has been described by Koontz, who attributes the innovation to Dr. Richard Sallade.<sup>1</sup> I have attempted it on numerous occasions but I have not found it to be particularly helpful. If one simply uses a suture through the eye in the Foley catheter to pull the end of the noninflated catheter back and forth through the urethra, the friction from the catheter on the urethral mucosa will evert the mucosa so that sutures can be placed with ease. In rare instances when this has not been sufficient, I have attempted to inflate the balloon as the authors and Koontz have suggested. In my experience this has not improved the exposure significantly.

*Patrick C. Walsh  
Department of Urology  
The Johns Hopkins Hospital  
Baltimore, Maryland*

1. Koontz, W. W., Jr.: A technique for placing sutures in the stump of the urethra for ureterovesical anastomosis following radical re-

#### REPLY BY AUTHORS

The single back and forth motion of the catheter has been abandoned by us since it is traumatic, will not bring the anastomotic site into a more superficial plane and does not completely assure selective urethral anastomosis. Therefore, we do not recommend its use but rather a correct application of the described maneuver. We find this acts fundamentally such as other authors who do the same by more complicated means.<sup>1</sup>

We would like to thank Doctor Koontz for the Editorial Comment reference to compare the similarities of a technique for the same purpose in radical prostatectomy. It is important to point out again the usefulness of this technique in cases of urethral trauma, for which we especially recommend its use and began its application. We also wish to mention the difficulties of being aware of local publications from other countries, especially if they are not included in the Index Medicus, such as the reference cited in the Editorial Comment.

1. Lange, P. H. and Reddy, P. K.: Technical nuances and surgical results of retropubic prostatectomy in 150 patients. *J. Urol.*, **138**: 348, 1987.