

Intrasinusal surgery

INTRODUCTION

Surgery of the renal calculus in any of its forms, and above all the staghorn, has developed a great deal in the last few years. One of the basic facts that has allowed us to do this has been the finding of a surgical approach to the renal sinus. This also made possible the development of intrasinusal surgery that allows us to remove calculi through the excretory ducts without damaging either the renal parenchyma or its vessels.

The other advance produced in intra-operative X-rays has been to get the third dimension of the kidney, by which we know the exact situation of a calculus in the renal space, this being the solution to the grave problem of residual calculi.

History

The renal pelvis has been approached from its anterior, posterior and inferior surfaces. The first pyelotomy was performed by Czerny, and simultaneously by Beck, consisting of a longitudinal incision on the posterior surface of an extra renal pelvis:

... incision that must not be prolonged either towards the parenchyma, so as not to damage the retropericolic artery, or to the pyelo-ureteral junction, so as not to cause a secondary stenosis . . . (Fey, 1925).

Due to the difficulty of uncovering the pelvis to localise and remove the calculi, other variants were described: the anterior pyelotomy upon the surface covered by the vascular pedicle, the inferior pyelotomy enlarged towards the inferior pole by a pyelonephrotomy and the enlarged posterior pyelotomy in which the incision is prolonged over the posterior lip of the renal parenchyma with section of the retropericolic vessels.

However, these enlarged pyelotomies did not bring a solution to complex lithiasis and this encouraged surgeons to adopt a more aggressive attitude after Hyrtl (1870) described an avascular line on the external edge of the kidney (that is neither real nor completely avascular) performing the bivalve nephrotomy, later called longitudinal or anastrophic.

Experience has shown that all pyelotomies which are enlarged to the parenchyma, Marion, Papin and Prather types, and particularly those of an extensive nephrotomy, involve serious vascular danger for the kidney and leave as a consequence an important diminution of its function, besides representing a risk to the patient's life, and also without the security of a total removal of the calculi.

Relapses as an operatory sequelae are more frequent than is thought and often they are only the answer to imperfect surgery (Truc & Gasset, 1960).

The knowledge of imperfect operative methods determined an abstentionist attitude towards complex lithiasis, although it was known that sooner or later a staghorn starts the destruction of the kidney.

The problem persisted until 1960 when we found an approach to the renal sinus that allowed us to see all the intrasinusal portion of the pelvis and the calyces without damaging the parenchyma or the vessels, and which is possible no matter what the degree of peripyelic scleromatose reaction. This approach, together with the transverse pyelotomy and the posterior vertical lumbotomy, form the two main pillars of the new renal lithiasis surgery that undoubtedly is less traumatic, involves no mortality, is more efficient and, above all, safer than the traditional surgery. Besides that, it has favourably changed the prognosis of complex and malignant lithiasis.

In 1974 all the bases regarding X-ray exploration of the kidney during the operation had been determined, representing a decisive aid in the detection and localisation of the smallest calculi and permitting their total removal with the minimum of trauma to the kidney.

THE RENAL SINUS: ANATOMICAL AND SURGICAL CONSIDERATIONS

The term sinus renalis was introduced by Henle in 1866 and he described it as a rectangular cavity situated within the kidney limited by two surfaces: anterior and posterior. Its external edge borders on the medulla in the parenchyma and its internal edge on the hilus (Fig. 6.1). This sinusal cavity has two prolongations, a superior and an inferior, and in each is contained one of the great calyces, each being lined by the internal sheet of the fibrous capsule of the kidney. The average dimensions of the sinus are: 5 cm vertically, 3 cm from the outside to the inside and 2 cm from back to front, although these are subject to great variability. The sinus is an anatomically closed space, that is to say, it is isolated from the retro-peritoneal space.

The morphological characteristics of the internal edge or hilar renal edge, that is to say, the hilus recess, are of great surgical importance. This has the shape of an oval fissure vertically elongated, 3.5 cm in height and 1.5 cm in width on average, but the shape, as well as the dimensions, vary notably from one individual to another. There are very small hili of 1.5 cm in height and 1.2 cm in width; these are the punctiform hili that can be observed in the malformed and anomalous kidney, and large hili of 7 cm in height by 2.5 cm in width, in shape of a vertical fissure, currently observed in the elongated kidneys. There is a series of variants such as the angular hilus, the semicircular, the outlined, etc., according to their embryological development. The renal hilus is limited by two lips, one anterior and retracted and another posterior and protruded which join in the higher part, and constitutes the superior commissure and, in the lower part, the inferior commissure. Finally, the more recessed the sinus and the more open the hilus the easier will be the intrasinusal surgery.

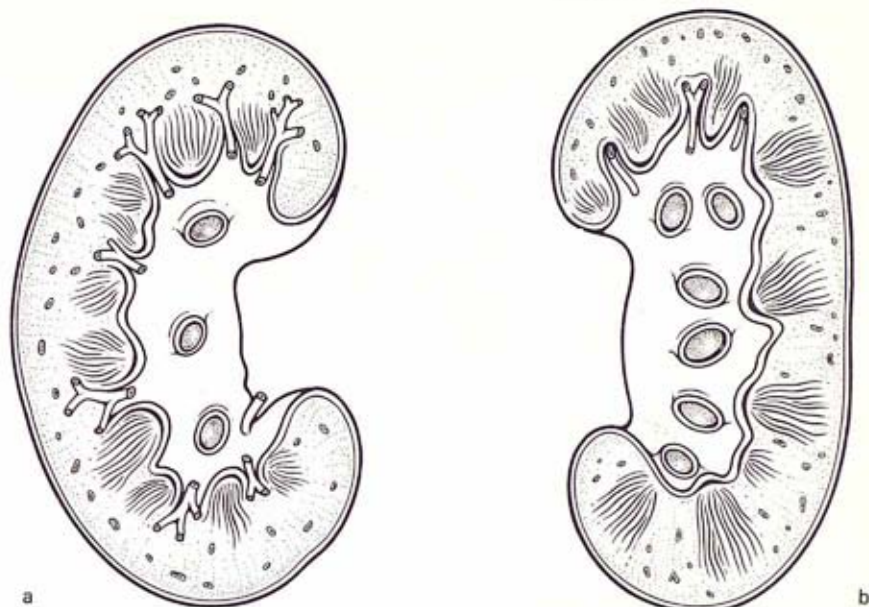


Fig. 6.1 Morphology of the renal sinus after its contents have been removed. (a) Anterior surface, (b) Posterior surface.

The sinus is occupied by the intra-renal portion of the pelvis, the calyces, vessels, lymphatics and nerves. The space between these two structures is filled by fatty tissue which facilitates the free movement of expansion and contraction of the calyces and of the pelvis within the sinus cavity (Fig. 6.2). The sinus is elastic,

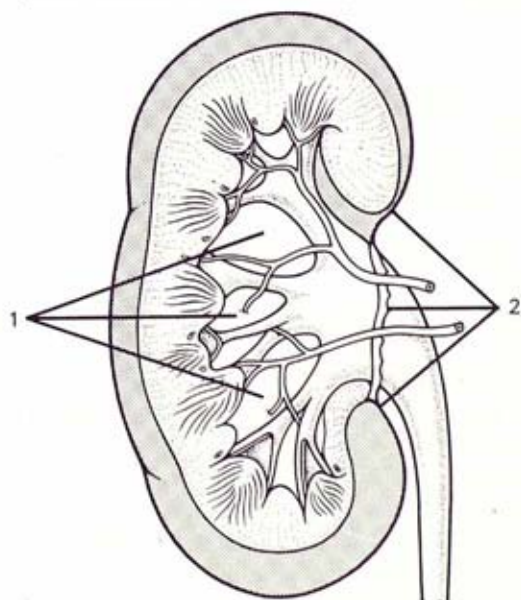


Fig. 6.2 (1) Renal sinus and its relationship with vessels, calyces and pelvis. (2) The entrance to the hilus is closed by an area of capsular adhesences (Taken from Narath: Renal pelvis and ureter. Grune and Stratton, ed. New York, 1951).

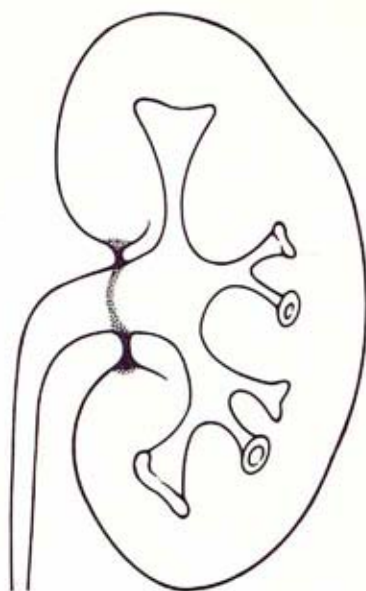


Fig. 6.3 The fibrous capsule sends a bunch of fibres which surround and adhere to the pelvis, forming the capsular diaphragm that closes the entrance to the renal sinus (from Narath: *Renal pelvis and ureter*, Grune and Stratton, ed. New York, 1951)

which allows an important amount of distension of the calyces, pelvis and vessels by various pathological processes, such as the formation of expansive processes, mainly cysts.

Disse (1891) showed that at the hilum the fibrous capsule of the kidney sends a bundle of dense and consistent fibres which surrounds and adheres to the extra-renal part of the pelvis, forming a capsular diaphragm (Fig. 6.3) which closes the entrance to the sinus and isolates it from the retroperitoneal space.

To the anatomist, as well as to the surgeon, the renal sinus presents as an unexplored cavity by simple inspection due to the renal hilum being too small and to the existence of the diaphragm that closes its entrance:

... the elasticity of the parenchyma allows us to lift the edge of the hilum and to uncover a large part of the pelvis when the kidney is healthy. But it is impossible in the lithiasic kidney because the sinus is closed by perinephritis ... (Fey, 1925).

... The agglomeration of vessels goes against all attempts of intrasinus pyelotomy ... (Paitre, 1941).

Our investigations have demonstrated that these concepts are not exact and we have proved that there is a detachment plane perfectly defined and individualised between the adventitia of the renal pelvis and the diaphragm that encloses it, (Fig. 6.4), and that this diaphragm could be cleared by blunt dissection without damaging any hilar or parenchymatous structure, including those cases with a strong sclerolipomatous inflammatory reaction. Further, once this diaphragm has been cleared the surgeon can penetrate the intrasinus space so that he can totally explore without damaging the vessels as there is no close adherence between the parenchyma and the excretory ducts because the internal sheet of the fibrous capsule and the intrasinus fatty tissue are interposed between them.

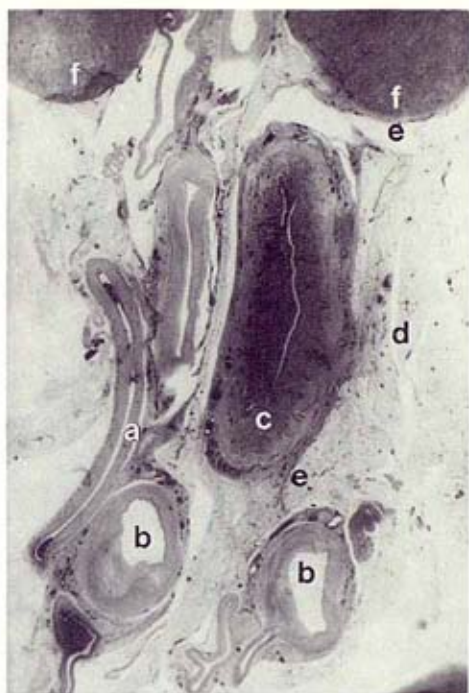


Fig. 6.4 Microphotography of a sagittal cut at the hilus level: a) veins, b) arteries, c) pelvis, d) fatty tissue, e) capsular diaphragm enclosing the pelvis, f) renal parenchyma

Summarising, this extracapsular approach to the sinus is based on the topographic disposition of the elements of the pedicle at their entrance to the renal hilus and their relation to the renal parenchyma within the sinus.

Although the vascular relationships of the pelvis are of little interest in this intrasinusal surgery, it is convenient to know the varieties of retro-pyelic arteries. This knowledge is useful in the freeing of the pelvis, avoiding damage to the arteries and for the placing of the retractors to avoid prolonged compression.

The retro-pyelic artery, which is never seen, branches off the common trunk at an acute angle and astride the superior edge of the pelvis. It then crosses behind it, sometimes on its extrahilar part and sometimes on its intrasinusal part. In the first case, when the artery passes slightly outside the posterior edge of the hilus, it is easily identified by palpation when freeing the pelvis. If it is covered by the peri-pyelitis we must consider it when the pelvis is of the totally extra-hilar type. Only in these rare cases does a remote possibility of damage to this artery exist if the peri-pyelic shell is excessively resected, particularly at the level of the superior commissure. But it is precisely in cases of the extra-hilar type of pelvis in which, no matter what type of lithiasis is present, it is unnecessary to enter the sinus space.

In all the other more frequent variants, in which the retro-pyelic artery runs through the interior of the renal sinus at a small or great distance from the posterior edge of the hilus, there is no danger of sectioning it (Fig. 6.5). The extracapsular surgical approach to the renal sinus runs inside the retro-pyelic artery with no possibility of damage to this artery or its branches.

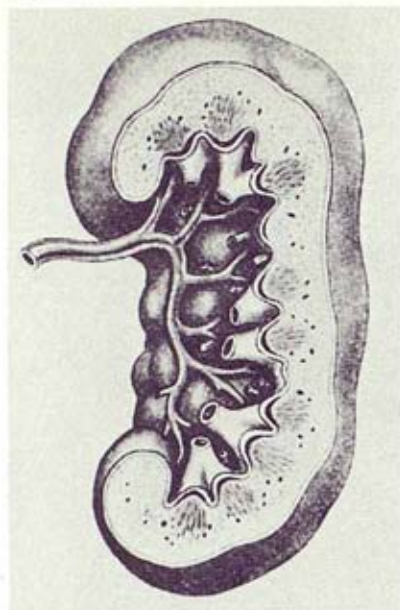


Fig. 6.5 Habitual intrasinusal disposition of the retropelvic artery within the renal sinus far from the posterior lip of the hilus

Technique

The normal sinus

To approach the normal sinus is very easy, the technique being very simple (Fig. 6.6). It consists of identifying the pyeloureteral junction then retracting the peripelvic fat towards the kidney by means of adequate curved scissors with blunt ends. The pelvic adventitia is separated from the peripelvic fat by blunt dissection.

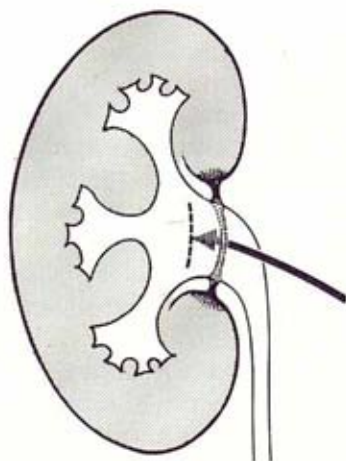


Fig. 6.6 Our extracapsular approach to the renal sinus without an inflammatory reaction. The arrow shows the approach to be followed when performing an intrasinusal pyelotomy: it is necessary to get in between the capsular diaphragm and the renal pelvis.

The scissors must progress in close contact with the adventitia. When passing underneath the capsular diaphragm, the scissors are opened vigorously, breaking the diaphragm circle, which does not resist. We are now at the entrance of the sinus and immediately a retractor ad hoc is placed, taking in the whole mass of peripyelic fat, the internal lip of the posterior edge of the kidney and the retropyelic vessels. All this is vigorously retracted upwards with no danger of tearing the parenchyma, as, being left protected by the capsule and the peripyelic fat, which is usually dense, it has great resistance and elasticity.

At this moment an open wet gauze is introduced into the sinus until it is totally filled. The gauze is then removed and another retractor of the same size or smaller is placed. Using both retractors, the posterior half of the kidney is firmly lifted, which makes the organ tilt, thus making visible the whole pelvis and the major calyces on its posterior surface. When this manoeuvre is performed correctly, it is completely blood free. Thus, in a normal kidney, the pelvis and calyces are now free within the sinus.

The pathological sinus

Easy exposure is not possible in pyelic lithiasis, especially when dealing with staghorns, due to the great modifications that lithiasis causes at the level of the kidney, particularly at the hilus, where the chronic inflammatory reaction of the perirenal fat is particularly intense around the pelvis.

The fat increases in consistency and quantity forming a dense shell of sclero-lipomatous tissue (peripylitis) of extraordinary importance, as much on the anterior surface as on the posterior, thus blocking the entrance to the hilus and therefore to the sinus. Nevertheless, according to our observations, these cases of hilar perinephritis modify the sinus fat very little.

These are the anatomical conditions that make conservative surgery difficult in renal lithiasis. But all these academic considerations do not approach reality. When peripylitis exists, which always is the case, it becomes somewhat difficult to find the surgical approach previously described. In this case the most advisable procedure is to identify the most superior and free part of the ureter and from there to follow a retrograde dissection with blunt-end scissors through the sclerolipomatous mass following a detachment plane which is always present between the pyelic adventitia and the peripylitis (Figs. 6.7-6.12).

It is advisable to free the posterior surface of the pelvis from the sclerosed shell that enwraps it (Fig. 6.13). This will facilitate a better operating field and ensure free pyelo-ureteral peristalsis in the future.

Resection of this sclerosed tissue must not be taken to the posterior lip of the kidney, but should stop a few millimetres before, to avoid the sectioning of the retropyelic vein and artery; thus a small strip of this sclero-lipomatous tissue must be left bordering the posterior lip, which, besides avoiding a vascular accident, will be used as supporting point by the retractors, that will lift the renal edge. In general, two small retractors, one on the superior commissure and the other on inferior, are preferable to one large one (Fig. 6.14).

To summarise, when there is a significant peripylitis, the freeing dissection of the pelvis and the entrance to the sinus are performed following the free ureter as a guideline. In any type of lithiasis access to the renal sinus is always possible.

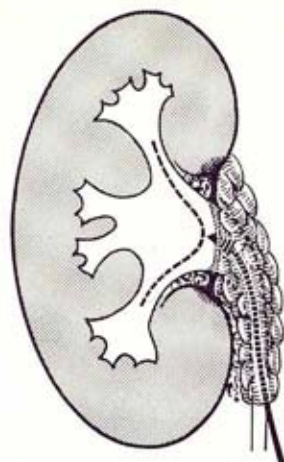


Fig. 6.7 The surgical approach to the pathologic renal sinus (peripylitis). Dissection starts at the level of the lumbar ureter.

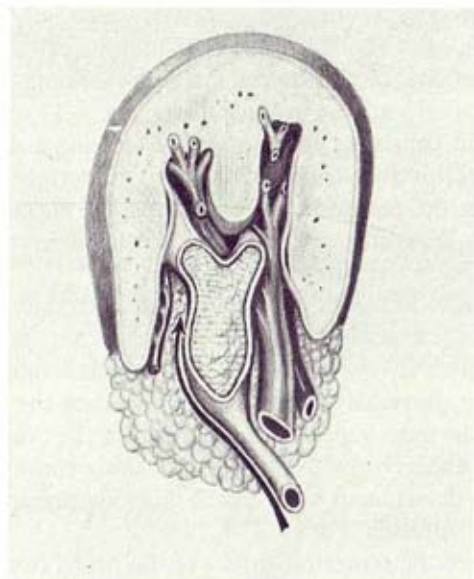


Fig. 6.8 Horizontal cut of a lithiasic kidney with peripylitis. The arrow points to the detachment space situated between the peripylotic fat and the adventitia of the pelvis.

Knowledge of the surgical anatomy of the renal sinus and of intrasinus surgery is essential for the practice of transverse pyelotomy (simple or enlarged) and for infundibulotomy. These are basic incisions in modern renal lithiasis surgery, and also in surgery of the dividing branches of the renal artery (aneurysms, stenosis, arteriovenous fistulae) in situ as well as in extracorporeal surgery.

Transverse pyelotomy

The difficulty in performing a pyelotomy depends on anatomical and pathological considerations. The shape, dimensions and situation of the pelvis in relation to the

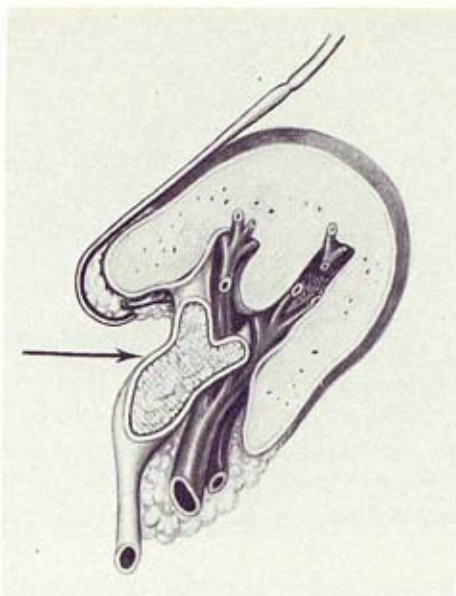


Fig. 6.9 The retractor lifts the posterior edge of the hilus protected by the peripyelic fat and exposes the intrasinusal part of the pelvis and calyces. The arrow indicates the situation of the transverse pyelotomy incision.

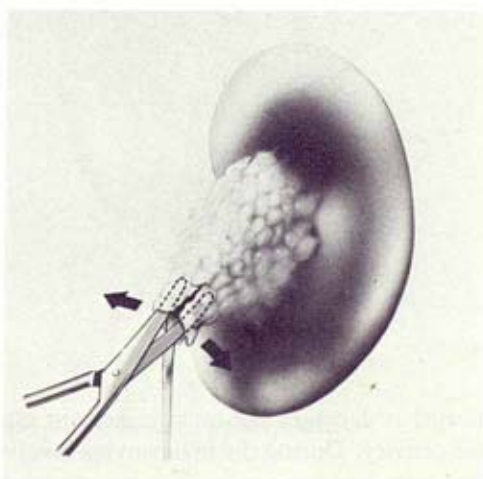


Fig. 6.10 Commencing blunt dissection in peri pelvic fat

renal parenchyma and the vessels vary. The small intra-renal pelvis was impossible to approach before the intrasinusal approach was known. The closed hili or punctiforms have also been a problem. The strong sclero-lipomatous reactions secondary to lithiasis increase the previous difficulties.

When Czerny practiced the first pyelotomy, he used a vertical incision. Ever since, this incision has been used as a routine without taking into consideration the anatomical and functional structure of the pelvis. The vertical pyelotomy has many

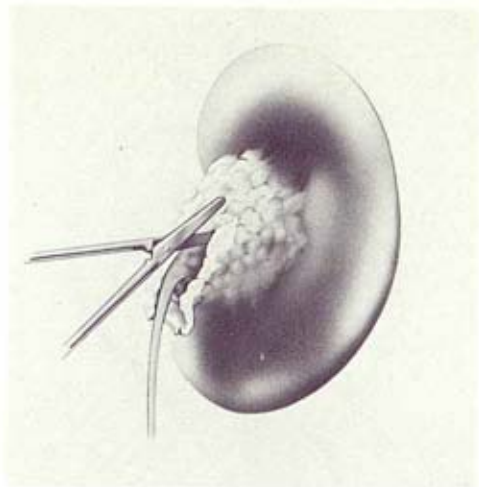


Fig. 6.11 Fat divided by sharp dissection

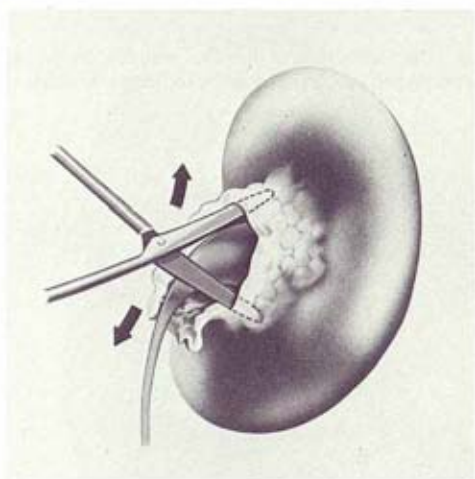


Fig. 6.12 Fat cleared from pelvis

and important handicaps: it damages the most important muscular fibres of the pelvis and alters motor activity. During the manoeuvres involved in the removal of a calculus, the incision tears and frequently damages the pyelo-ureteral junction, which can cause its stenosis or dysfunction of the possible pacemaker regulating the physiology of the upper excretory tract. The leakage of urine, although temporary, is very frequent and must be considered as a surgical complication, not as an important fact per se. It is much more important than is thought because of its late sequelae: namely, the intrinsic stenosis of the ureter. This causes urinary dysfunction and lithiasic relapses, prolongs hospitalisation of the patient and makes any future reoperation more difficult.

When in 1960 we rejected the dogma of the vertical pyelotomy and favoured the transverse pyelotomy, we did so based on studies on the functional anatomy of the

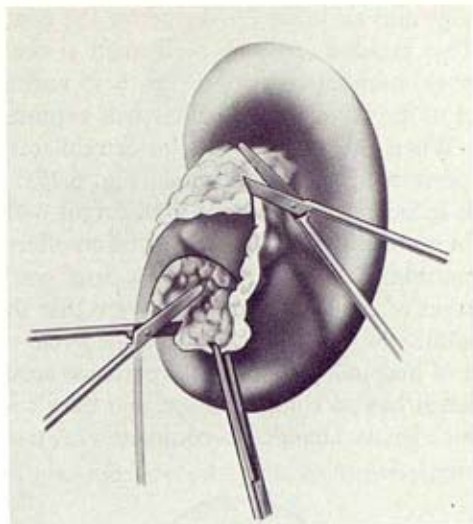


Fig. 6.13 Excess fat excised

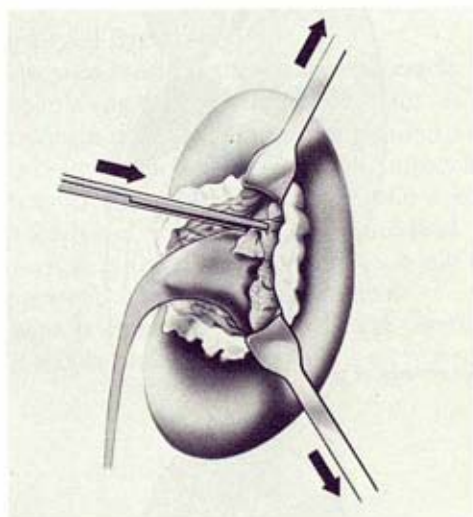


Fig. 6.14 Fat retracted from pelvis with author's own retractors

ureteric musculature. These showed that this excretory tract is not formed, as the classics described it, of two muscular layers, an internal and longitudinal and another circular and external, but is constituted of a system of spirals that run along the whole organ; these spirals do not all run in the same direction but take opposite directions and cross over each other. This system of spiralled bundles adopts a different inclination according to its position in the excretory tract, so at the superior end, in the pelvis, only 'circular fibres' exist, that is to say, stretches of very gentle inclinations of the muscle spirals.

Thus, transverse pylotomy is the most logical and anatomical incision. Being performed in the same direction as the pyelic musculature it does not alter the

pyelo-ureteral physiology and excludes the danger of the continuation of the tear towards the ureter. This incision must be performed at the middle part of the pelvis, far from the pyelo-ureteral junction (Figs. 6.15 and 6.16) which permits one to see the entrance of the calyces and facilitates its exploration under visual or instrumental control. When the pelvis is of the extrahilar type, the pyelotomy incision must not be performed within the sinus (Fig. 6.17).

The suturing of this incision must be done with catgut 6-0; a thicker catgut is not recommended. The suturing of a transverse incision offers a greater resistance to tearing than a longitudinal one. This suturing does not decrease the pelvic calibre. Other advantages of transverse pyelotomy are that there is no outflow of urine, there is no possibility of lesion or stenosis of the pyelo-ureteral junction and it shortens the period of hospitalisation. The experience accumulated during the last 15 years shows that it has no complications, and that it is far superior to the vertical pyelotomy which I have abandoned completely. A pyelotomy must not be

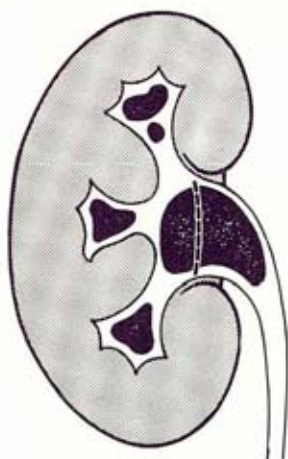


Fig. 6.15 Site of incision for removal of pelvic stone

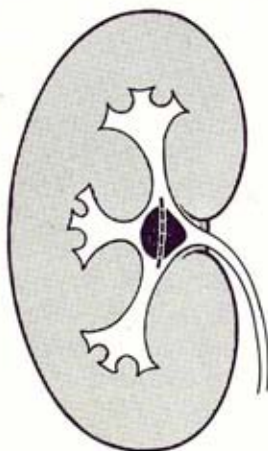


Fig. 6.16 Site of pelvicotomy for removal of small intra-renal pelvic stone

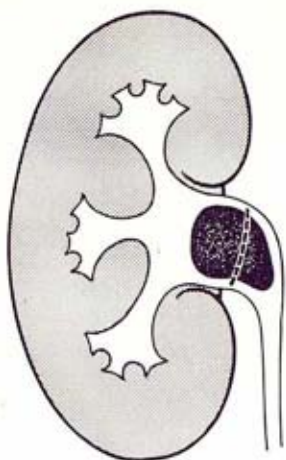


Fig. 6.17 Site of pelvicotomy for removal of stone in dilated extra-renal pelvis

sutured before previously checking the permeability of the ureter along its whole length.

Infundibulotomy (enlarged pyelotomy)

When trying to remove a calyceal calculus of a considerable size then, we perform the longitudinal incision along the calyceal infundibulum (Fig. 6.18). This infundibulotomy incision does not affect the calyceal motility as its muscle sheath is longitudinal. Such incision, which also affects the 'musculus sphincter calycis', solves the dysfunction of the calyceal disectasis while performing the sphinterotomy of the pyelocalyceal junction. The longitudinal incision of the calyx must not reach the fornix, as the retrocalyceal veins would then bleed. Although their damage is unimportant, it makes visibility difficult.

When the renal hilus is closed or very small, calycotomy is difficult and not always possible. This occurs rarely in adults, but is more frequent in children, and

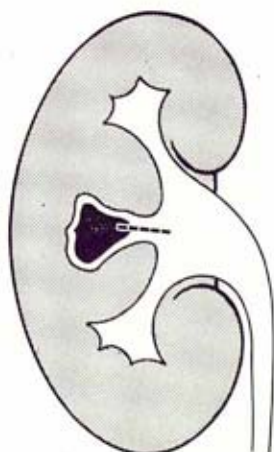


Fig. 6.18 Site of calycotomy for removal of calyceal stone from dilated calyx

the calculus must then be removed by means of an intrasinus transverse pyelotomy that allows the identification of the calyceal orifice, dilatation and introduction of the forceps through it for removal. When the neck of the calyx is small or is disectasic, it must not be sutured. The secondary epithelisation from its edges will then give a greater width to the calyceal neck, thus allowing its emptying without difficulty.

In staghorn calculi and in some pyelocalyceal lithiasis the ends of the transverse incision are prolonged towards the superior and inferior calyces. This incision is therefore longitudinal upon the calyces and transverse over the pelvis and being far from the pyelo-ureteral junction finally results in a pyeloinfundibulotomy, that is to say, an enlarged intrasinus pyelotomy. This arched incision can be varied according to the morphology of the pelvis and the staghorn (Fig. 6.19). The convexity of the incision must be performed near the pyelic vertex of the calculus

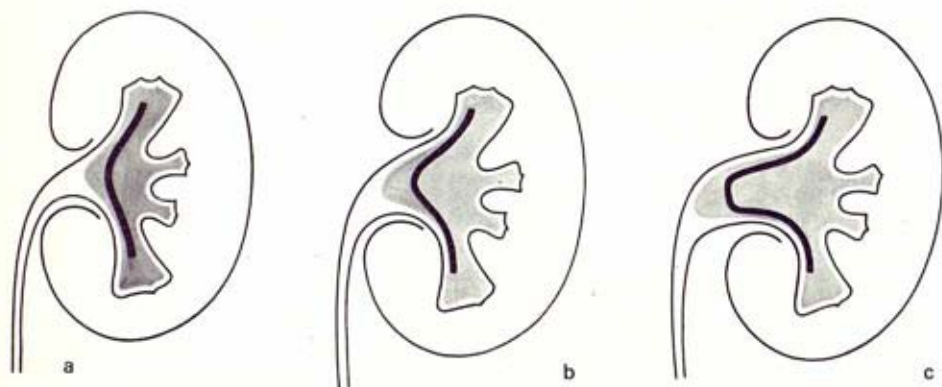

Fig. 6.19 a, b, c— Variants to the intrasinus enlarged pyelotomy incision according to the morphological characteristics of the renal pelvis

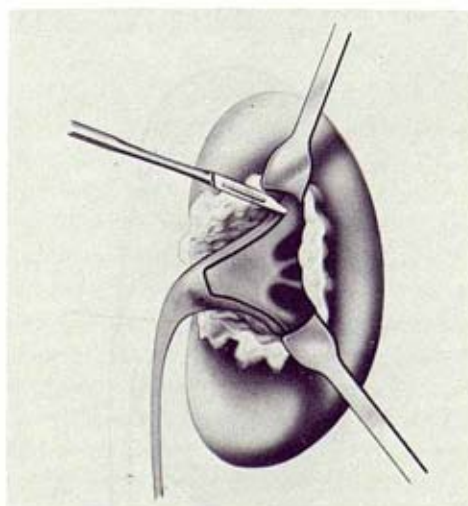


Fig. 6.20 Retraction of renal parenchyma from collecting system

to allow us to luxate it easily with no danger of tearing, but must be as far as possible from the pyelo-ureteral junction.

The pyelic and infundibular incision is performed within the sinus with a small, fine scalpel (Fig. 6.20) and must be carefully perpendicular to the tissues. The tracing of this incision is simple when the tissues are cut over the hard body of the calculus. The edges of the incision must not be clamped or used for placing reference stitches. When these edges are manipulated, as happens during the suturing, very fine atraumatic dissecting forceps should be used.

Removal of the staghorn

It is best to follow a method based on a detailed X-ray study (antero-posterior, internal profile, oblique at different angles and projections) pre- and intra-operative. This is necessary not only to localise the free calculi but also to study the lines of force of the calculus, the branches and axis, and the direction in which the traction manoeuvres for removal must be applied, because staghorn calculi must *never* be wrenched out. They must be gently mobilised from their fixation points and from all the obstacles presented on their removal. Gentle traction must then be applied upon two or more points to avoid their fracture and, by means of these manoeuvres to start luxation. Basically the staghorn is always presented as a triangle within a cavity presented by the pyelic vertex.

The first consideration to be taken into account is to perform a pyelic and infundibulo-calyceal incision that can allow:

1. The greatest possible access to the internal branches of the lithiasic triangle.
2. The luxation of the pyelic angle.
3. The removal of all calculi.

The second consideration is to avoid, by all means, the damage caused by instruments to the mucosae of the excretory tracts. For this purpose it is fundamental to use blunt instruments always and to operate under visual control. The introduction of fingers must be avoided and in those calyces which are not visible, the infundibulum should be gently dilated with adequate forceps.

The third point is to avoid damaging the renal parenchyma. This is the key point in the concept of intrasinusal surgery. Once the enlarged pyelotomy incision has been made, the first manoeuvre to be performed is the luxation of the pyelic vertex of the triangle (Fig. 6.21). This is an easy manoeuvre that must be done by means of a malleable stiletto, mobilising the lateral and inferior surfaces of the vertex of the calculus with respect to the incision of the pelvis.

The luxation of the pyelic angle allows one to expose 60 to 70 per cent of the calculus (Fig. 6.22). Afterwards another branch of the lithiasic triangle is luxated and removed—by a very delicate manoeuvre. Generally speaking, and applying all the data obtained by the previously mentioned X-ray studies, we must attempt to remove the branch that seems the more mobile and shorter (Fig. 6.23).

It is important at this stage always to act along the 'mobilisation axes' of the calculus. These are marked amongst the points that must run a shorter distance for their exteriorisation through the incision. It is also important to take into consideration the 'free spaces' that is to say, those calyco-infundibular cavities that allow partial mobilisation of the calculus and exteriorisation of one of its embedded

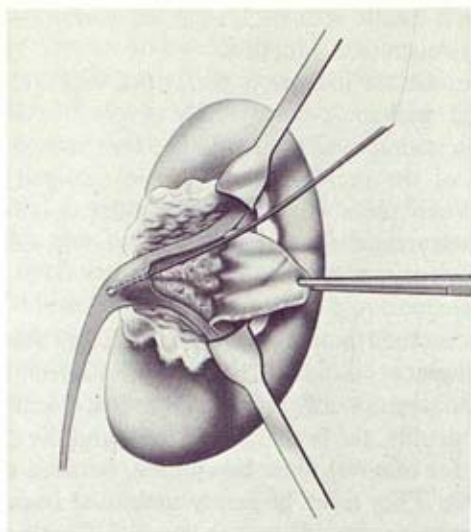


Fig. 6.21 Pelvicotomy to remove major pelvic portion of a staghorn calculus

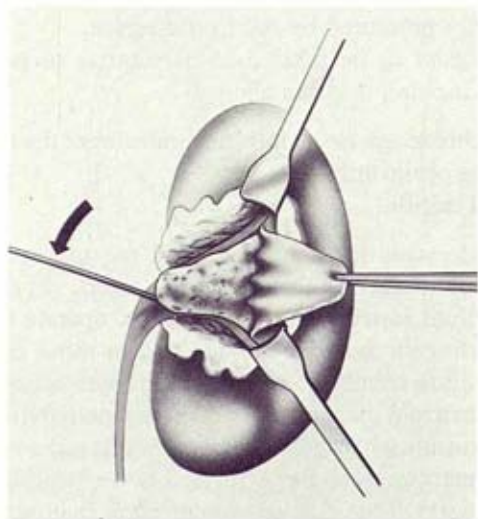


Fig. 6.22 Application of leverage to elevate pelvic portion of staghorn calculus

branches. Sometimes this mobilisation in order to dislodge a branch, will be done toward the inside of the kidney, and not outwards as would seem logical.

If the exteriorisation of the second branch is particularly difficult we must dilate the neck of the calyceal infundibulum, which is the more rigid segment. This is done using very fine, long mosquito forceps of adequate curvature and by opening them gently. After mobilisation and exteriorisation of the second branch, the remaining calculus follows easily. Only in those calculi with a big middle branch or orientated in a sagittal plane to the body of the calculus, will we have to proceed again to careful mobilisation manoeuvres, traction along the mobilisation axes and making profitable use of the free spaces.

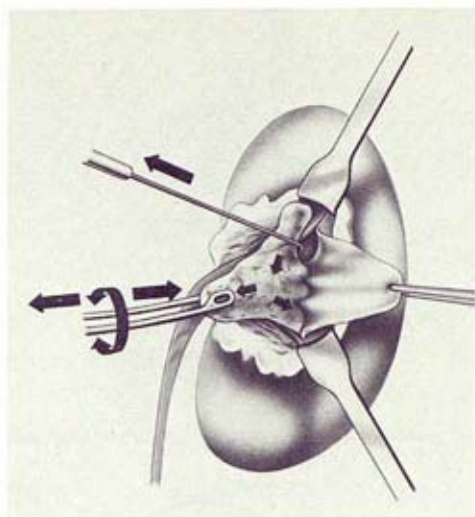


Fig. 6.23 Use of stone forceps and hook to mobilise calculus in calyceal neck

The manoeuvres for the removal of a staghorn are simplified. Firstly the pyelic vertex and its superior or inferior prolongation calyceal branch must be removed followed by the remaining infundibulo-calyceal calculus. This manoeuvre will be facilitated by the free space left by the portion of the staghorn removed in the first instance.

So far we have followed the most desirable method but this is not always possible for removal of the whole calculus. Very often when it is a uric acid staghorn of a very hard consistency and smooth and regular—including those made up of ammonium magnesium phosphate—it is impossible. It is rarely possible with calcium phosphate calculi, which are very friable and whose branches break at the slightest mobilisation exerted upon the pyelic vertex; these breaks take place at the narrowest part of the calyceal prolongations.

When this is impossible, and to avoid damaging the intra-renal excretory tracts or the parenchyma, it is preferable to break the calculus, which must be done *without violence*, proceeding to break the branch that holds the calculus to the greatest extent and which presents greater difficulties of removal. One can then proceed to the dilatation of the infundibular neck or to prolongation of the incision even more at the level of the whole calyx, and to subsequent removal, as if it were a calyceal calculus.

Remaining calyceal calculi

After the removal of the body and principal branches of the staghorn we proceed to three-dimensional X-ray exploration of the kidney.

Intra-operative X-ray control is *basic and absolutely necessary*. If not available to the surgeon it is preferable not to operate as complete removal of the calculus cannot be assured.

When a spatial and exact idea of the remaining calculi has been achieved, we proceed to a systematic search by areas. The finger must not be introduced to

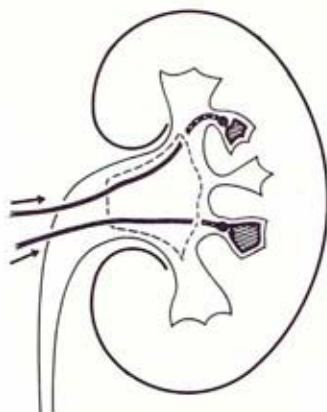


Fig. 6.24 Use of fine irrigating cannulae to mobilise peripheral stone fragments

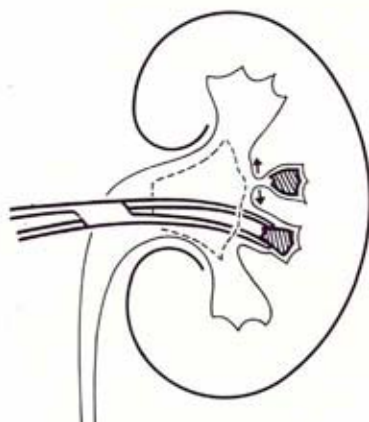


Fig. 6.25 Removal of peripheral stone fragments with forceps after dilation of calyceal neck

check and localise a calculus or a fragment. The exploration must be done with a malleable stiletto with a small rounded end which communicates the sensation of rubbing against a foreign body to the hand of the surgeon (Fig. 6.24).

A visual exploration is frequently performed by the surgeon, particularly of the middle calyceal group, because its infundibulae empty perpendicularly into the incision of transverse pyelotomy and to the visual plane of the surgeon. Once the existence of the calculus is checked and is found to be bigger than the infundibulum through which it must be removed, we proceed to dilate it (Fig. 6.25).

This manoeuvre must be performed gently to avoid haemorrhage that can disturb vision. If this is produced, the calyx is obstructed by a swab while we proceed to search for the other calculi, whose situation we know through successive intra-operative X-rays, until total removal is achieved. The operation is completed by suturing the pyelotomy but not its calyceal segment (Fig. 6.26). Once the retractors are removed the posterior lip of the kidney covers the enlarged pyelotomy (Fig. 6.27).

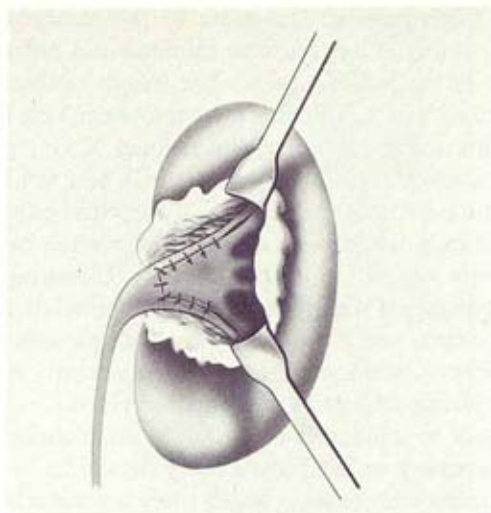


Fig. 6.26 Interrupted suture of the pyelotomy following stone removal

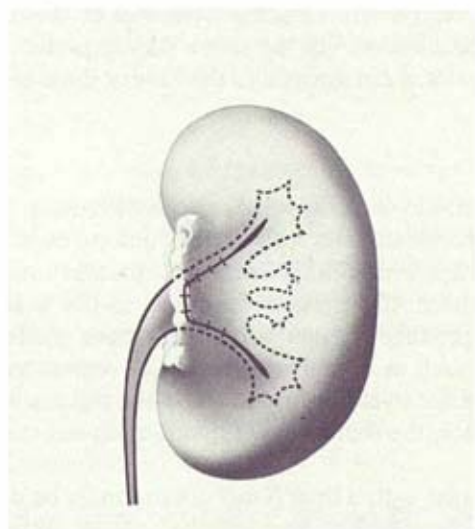


Fig. 6.27 Replacement of the renal parenchyma following suture of pyelotomy

Complementary nephrotomies

Long experience has shown that the vast majority of staghorn calculi (75 per cent) can be totally removed through the enlarged intrasinusal pyelotomy. Nevertheless in some cases (25 per cent) the enlarged pyelotomy must be completed by one or more *small* nephrotomies, under the following circumstances:

1. A very big calyceal cavity, full of calculi and with a thin parenchyma.
2. A big calculus localised within a calyx with long and narrow infundibulus.
3. A calculus localised in an ectopic calyx.

Nephrotomy is a complementary measure to the enlarged pyelotomy and is always used as a last resort. They must be minimal and radial and fall upon the most peripheral area of the lithiasic calyx. The length of these incisions must be equivalent to the thickness of the calculus to be removed. This is possible thanks to their exact localisation using the three-dimensional X-ray; prior to each small nephrotomy the renal artery is clamped with a small, *very soft* bulldog clamp. It is not clamped when the nephrotomy falls upon a very thin parenchyma. Clamping must not exceed 7–9 minutes, enough time to remove the calculus, explore and wash the calyceal cavity and suture the nephrotomy. Clamping can be repeated as many times as are necessary if the intervals in which circulation is restored are the same as the ischaemia time and if the kidney does not present signs of vasospasm. To prevent this, a normal blood volume must be constantly maintained and traction of the pedicle during freeing of the organ avoided—particularly when the kidney is exteriorised to obtain X-rays. With the contact mini-chassis now available, it is not necessary to bring the kidney outwards.

In the fortunately infrequent cases in which there is great arborisation of calyces, intra-renal pelvis, tightly closed renal hilus and re-operations, and in those in which it is expected to perform multiple nephrotomies, it could be advisable, 30 minutes prior to the clampings, to give mannitol or frusemide. The osmotic diuresis has some protective effect against ischaemia of the renal cell. Nevertheless hypothermia is unquestionably the safest way to preserve the renal function when in certain exceptional circumstances the kidney must be rendered ischaemic for several hours.

Cavity wash-outs

It is useful and necessary to wash the renal cavities with warm normal saline (37°C). The washing must be atraumatic and carried out in each one of the calyces, including those which are non-lithiasic as mucoprotein matter not detected by X-rays can dwell therein. The pressure imparted to the wash-outs must be *low*, otherwise one can produce lesions similar to those made during retrograde uretero-pyelography such as calycular, lymphatic, venous and interstitial reflux, which are causes of acute pyelonephritis. When the renal artery is clamped, with no peripheral resistance, the reflux caused by the wash-out can be most harmful to the kidney.

At the end of the wash-out, a final X-ray control must be done. We must never close a lumbotomy without making sure that the removal of the calculi is complete.

Nephrostomy

As a principle, when dealing with reno-ureteral lithiasis we are against the urinary diversion, both ureteral and by nephrostomy. However, we make an exception with certain staghorns.

In large, sclerosed intra-renal cavities, sometimes non-reducible, that have contained a friable staghorn and mucoprotein matter, and have shown persistent infection—particularly with *B. Proteus*—we perform an axial minimal nephrostomy with a small multi-perforated silastic tube (Fig. 6.28). Five to six days after operation the permeability of the ureter is checked, by an IVP, for the absence of leakage. We then connect a chemotherapeutic solution drip for 2–3 days. It is very

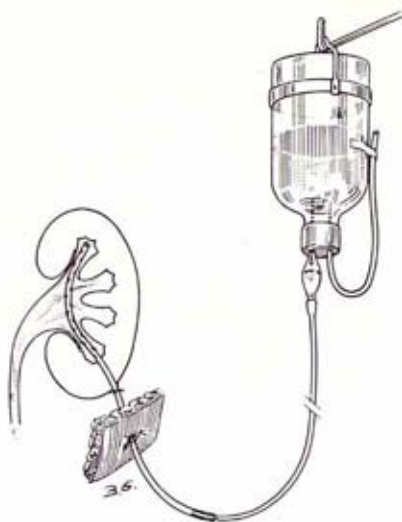

Fig. 6.28 Minimal axial nephrostomy with a multiperforated tube connected to a drip of antiseptic solutions

efficient as a local treatment of infection and also washes out germs, casts, cellular detritus, fibrin, etc. Frequently we get a negative urine culture and the end of treatment.

Instruments

For this type of surgery it is essential, besides a fine aspirator, to use renal sinus retractors (Fig. 6.29) whose amplitude, curvature and depth adapt to the thickness of the posterior lip of the renal hilus. The edges are blunt, the handle long and rigid. There are different sizes for the different morphological variants of the hilus, for the adult as well as for the child. These retractors keep the kidney fixed and tilted, at the same time exposing it and they also present the hilar edge perpendicularly to the surgeon.

For the enlarged pyelotomy two narrow retractors are placed, one on the superior commissure and the other of the inferior. For the simple transverse pyelotomy a single, somewhat wider retractor is used.

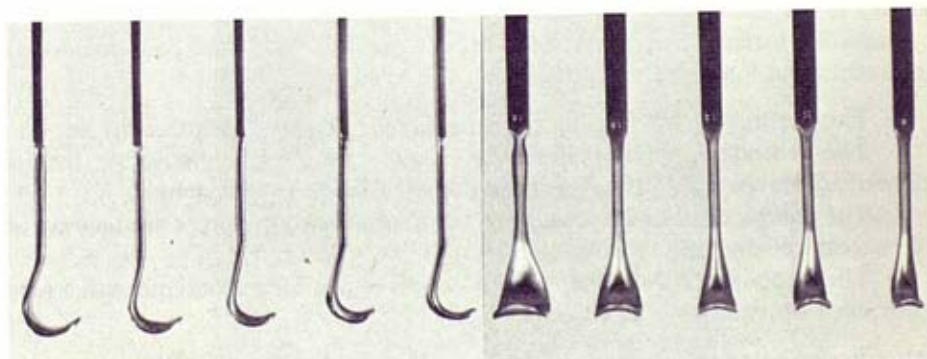


Fig. 6.29 Set of sinus retractors of different sizes

If the operation takes longer, it is advisable to loosen the retractors as they might press the retro-pyelic vessels—manifested by the change of colour of an area on the posterior surface of the kidney. Frequently the retractor causing the compression is the one situated at the superior commissure at the level of the origin of the retro-pyelic artery and compression may be due to too vigorous traction by the assistant or because the retractor is too closed.

Parietal incision

For simple renal lithiasis the posterior vertical lumbotomy is used routinely, including very obese and kypho-scoliotic patients, and has neither contra-indications nor complications. It is an atraumatic incision, neither muscles nor nerves are sectioned and it affords an excellent exposure. The renal pelvis and the ureter are reached directly with no need to free the kidney. Usually a patient who has had a calculus removed from the intra- or extra-renal pelvis through this parietal incision, associated with transverse pyelotomy, is discharged from hospital between the third and fourth postoperative day. Due to its innocuous nature in bilateral lithiasis we routinely perform the double operation in one surgical procedure. This approach is also used for some simple pyelocalyceal lithiasis, including simple staghorns and presents no problems in taking contact intra-operative X-rays in the antero-posterior position. However, this incision requires a longer period of training for the surgeon.

In complex renal lithiasis, the preferred incision is postero-lateral lumbotomy with resection of the 12th rib, near its articulation. The extreme posterior prolongation of the lumbotomy is the key to a good exposure of the hilar edge of the kidney which is the one that really interests the surgeon.

Indications

We perform this type of conservative surgery in most of the different forms of lithiasis and particularly in all staghorns (Figs. 6.30–6.33), except in the kidney responsible for systemic infections and the non-functioning kidney, which is demonstrated by gammagraphy. The absence of contrast elimination in an IVP, even in the most retarded plates, must not be interpreted as indicating an irrecoverable kidney, nor must the peroperative confirmation of a lithiasic pyonephrosis mean that conservation surgery should be abandoned, above all if the other kidney is normal.

Including patients with renal insufficiency following urolithiasis, our position is interventionist for the following reasons:

1. This technique causes minimal or no damage to the renal parenchyma.
2. The secondary nephropathy to a uropathy is much more stable than a primary nephropathy, as long as the urological factor has been solved.
3. The patient can be adequately prepared and if necessary kept on dialysis for the necessary length of time.
4. The technique of fluid regulation allows us to operate on patients with a very poor renal function without deterioration.

Also, in non-obstructive cases of lithiasis we operate because the infection cannot be eradicated unless all calculi are removed. However, a urinary infection is very

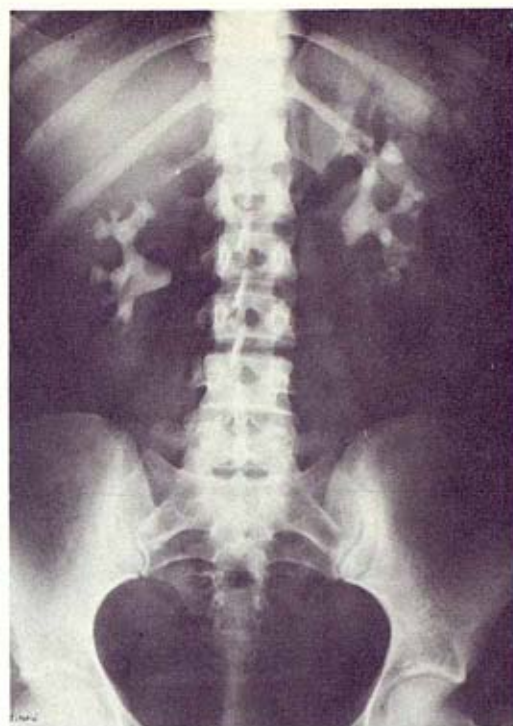

Fig. 6.30 (Ob.I) Simple X-ray. Bilateral staghorn.

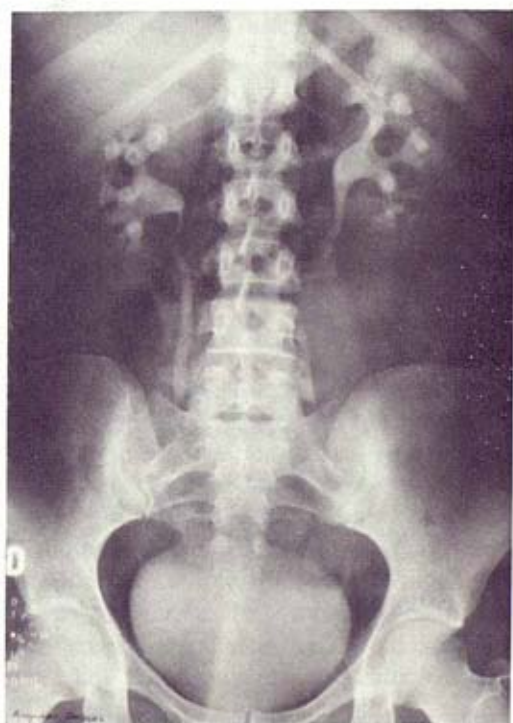

Fig. 6.31 (Ob.I) Pre-operative I.V.P.

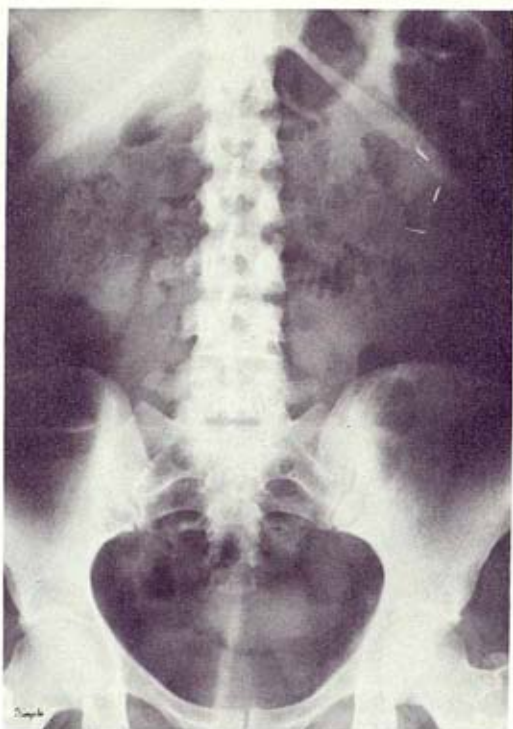

Fig. 6.32 (Ob.I) Simple post-operative X-ray. Total removal of the calculi. Those of the right kidney were removed through an enlarged pyelotomy and the left kidney through enlarged pyelotomy and two complementary nephrotomies.

difficult to cure if the patient has advanced renal insufficiency, even if his urinary tracts are normal. If the renal insufficiency is terminal and irreversible the patient can be a candidate for chronic dialysis or renal transplant after all the infective foci have been removed.

In conclusion we can say that at present, there are no contra-indications to the operative treatment of lithiasis with renal insufficiency.

Complications

The removal of calculi through the excretory tracts does not require the administering of blood or clamping of the renal artery. The average time for the removal of a staghorn is 3 hours. The fistula rate in these cases was 6 per cent. Urinary fistulae or late haemorrhages are not noticed nor is secondary narrowing of the pyelo-ureteral junction or hypertension. Infection of the wound or haematomas are noticed with the same frequency as in other renal incisions. The only important postoperative haemorrhagic complication was noticed in those cases in which, as a complement to the enlarged pyelotomy, it was necessary to perform multiple small nephrotomies and in which blood transfusions were necessary. Intrasinusal surgery has no mortality. The hospitalisation time is shorter and more comfortable to the patient. The percentages of missed calculi and recurrences has been much lower than in those with classic surgery.

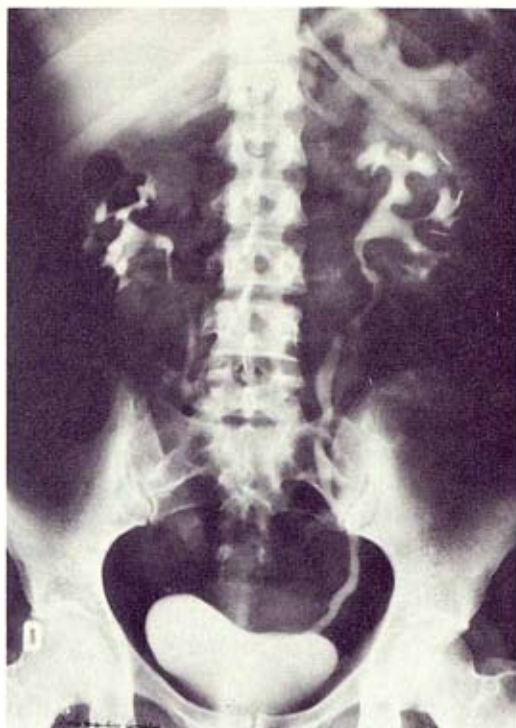

Fig. 6.33 (Ob.I) Post-operative I.V.P.

After 20 years of experience in intrasinusal surgery, we have reached the conclusion that this surgery is the least aggressive of all the recommended operations for the removal of renal calculi. The latest advances obtained through intra-operative X-ray control consolidate and reinforce the efficiency of this method.

REFERENCES

- Disse, J. S. G. (1891) In Groeve, J. G. (ed.) *Anatomie van den mensch*, Rotterdam
- Disse, J. S. G. (1891) *Allgemeine anatomie*. In Merkel, F. S., Bonnet, R., (eds) *Anatomische Hefte*, Wiesbaden
- Fey, B. (1925) L'abord du rein par la voie thoracabdominale. *Archives Urologiques de la clinique de Necker*, Vol 5, 1925-1927
- Gil-Vernet, J. M. (1965) New surgical concepts in removing renal calculi. *Urologia Internationalis*, 20, 255
- Gil-Vernet, J. M. (1970) La cirugía intrasinusal de los calculos coraliformes. *Proceedings of the XVth International Congress of the Urological Society*, Tokio, Vol 1, p. 11
- Hyrtl, J. (1870) *Das Nierenbecken der säugetiere und des Menschen*. Wiener Sitzungsberichte, B, LIV
- Paitre, F., Giraud, D. & Dupret, S. (1941) In Salvat, (ed.) *Anatomoquirúrgica ilustrada. Los elementos del pediculo, enfasc.*, Vol 3, p. 255, Barcelona
- Truc, E. & Grasset, D. (1960) Lithiase rénale. *Encyclopedia de Médecin et Chirurgène*, 9, 5