

DESCENT OF THE RIGHT RENAL VEIN

J. M. GIL-VERNET

From the Department of Urology, School of Medicine, University of Barcelona, Barcelona, Spain

ABSTRACT

A new operation is described, in which the right renal vein outlet is moved to a lower level on the vena cava, helping to decrease the distance between the kidney and the bladder. This procedure permits treatment of extensive obstructive wounds of the pyeloureteral junction or lumbar ureteral junction, caused by lithiasis and ureteral and renal operations, that cannot be treated with conventional operations. Renal circulation is not altered with this procedure. The operation is simple, does not cause complications and provides excellent results.

One problem faced in our specialty is the therapeutic direction to take because of consequences of lithiasis and ureteral and renal operations. Obstructive wounds at the pyeloureteral or lumbar ureteral junction are not uncommon after pyelolithotomy lengthwise on a small pelvis, one intrarenal or when the pelvis is absent, as in patients with a bifid ureter. These scar wounds, which have a large fibrosclerotic content, cannot be treated with pyeloureteroplasties but require ample resection and anastomosis. While excretory urography (IVP) demonstrates the height of the obstructive wound and its influence on the kidney, it does not reveal the degree of fibrosclerosis above and below the stenosis. This fibrosclerosis usually is more extensive than believed initially and must be desiccated to achieve good anatomical and functional results.

When scar stenosis is limited it can be resolved by freeing the kidney and dissecting the pedicle, which permit the kidney to be lowered slightly and, thus, enable resection and anastomosis without tension. However, problems arise when the wounds are extensive. Years ago ureteroileoplasty provided acceptable results in such cases but, lately, this procedure has been replaced by autotransplantation, which is a logical and convincing operation since there is no better substitute for the ureter than the ureter itself. Based on this theory, we have looked for a less serious operation than autotransplantation for wounds measuring more than 2 but less than 6 cm. Herein is proposed an intermediate solution for the right side, which consists of lowering the renal vein graft.

ANATOMICAL BASIS

Anatomically, the operation is elementary and convincing. Among the various procedures to fasten the kidney the pedicle is the one of interest to us for reasons that go beyond the fastening problem and refer to the operation itself.

From its aortic origin at L1 the right renal artery goes obliquely downward, outward and backward, and penetrates the renal hilus at L2 and L3, forming a 60-degree angle with the aorta. In ptosis this angle is more acute and closes. An important factor is that the artery is longer than the vein. The renal artery provides collateral branches to the suprarenal artery, the diaphragmatic columns and the lymphatic ganglions, which are anastomosed with those parallel to the neighboring branches. Therefore, they can and should be tied so that the artery has a larger field of movement.

The right renal vein also goes obliquely downward and outward in the same direction as the artery but the angle is less pronounced. The vein is exclusively at the service of the kidney and is shorter than the artery. However, the graft is closer to the kidney than to the artery.

CLINICAL DATA

Clinically, when the pendulum falls circular movement takes place around the vascular pivot. When the kidney falls the ureter remains sinuous but folds like an accordion or becomes elbow-shaped, which is more noticeable when the degree of prolapse is great. However, a surgical observation suggested the possibility of lowering the right renal vein. When the kidney was freed and the pedicle was dissected, voluntarily provoking ptosis, it could be seen that it is the vein and not the artery that opposes the greater descent. Therefore, it was concluded that the height of the renal vein graft (being closer to the kidney) determines the degree of renal descent. As a result, if the renal vein outlet is lowered and simultaneously disconnected from the rear surface of the vena cava to facilitate the pendular movement of the corresponding artery, the kidney can be lowered 5 and 10 cm. without tension or a decrease in the artery caliber. Consequently, by decreasing the distance between the kidney and the bladder the ureter is more than sufficient and flexible, and up to 6 cm. can be resected, in the most favorable cases, and reanastomosis can be done without tension at the ends.

The new renal vein outlet is not in a counter-direction but is located at right angle to the vena cava. Thus, the return renal circulation is not modified, especially when there is a negative pressure on the lumbar vena cava.

APPLICATIONS

The operation is applicable to patients with scar stenosis that is not too extensive at the pyeloureteral or lumbar ureteral junctions (fig. 1, A) and high, irreparable ureteral fistulas, which all too frequently constitute iatrogenic pathology of the longitudinal pyelolithotomy and ureterolithotomy and could be avoided with a transverse-type incision.^{1, 2} The procedure also is applicable in rare cases of ureteral trauma incurred during an appendix or colon operation, in which the loss of substance impedes direct anastomosis of the ends.

SURGICAL TECHNIQUE

The kidney is freed from superficial or deep wounds caused by previous operations. Then, the renal artery is freed carefully up to the aorta, the small collateral branches are tied and the side of the vena cava, above and below the outlet of the renal and gonadal veins, is dissected. The ureteral or stenotic pyeloureteral or fistulous segment is resected, making certain that the sclerotic tissue is eliminated completely and that a simple anastomosis between them is possible.

Next, the rear surface of the vena cava is disconnected to permit pendular movement of the renal artery. To facilitate a greater movement it is necessary to tie and section the lumbar vein at its caval outlet in some cases. Immediately after the artery is clamped with a soft bulldog clamp a Satinsky clamp

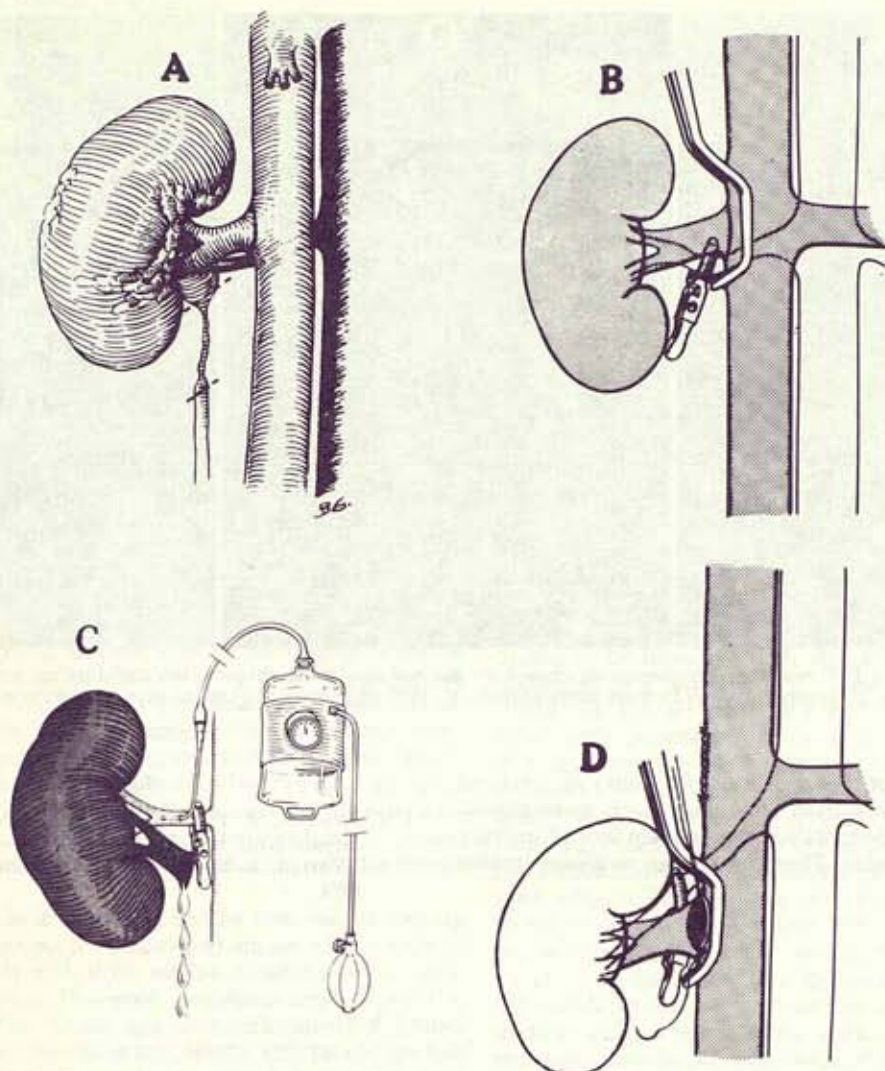


FIG. 1. A, resection of postoperative scar stenosis at pyeloureteral junction and lumbar ureter. B, placement of bulldog clamp on artery and Satinsky clamp sideways on vena cava. C, renal vein section at outlet. Puncture of artery and perfusion with 4C solutions were done to achieve renal hypothermia. D, renal vein anastomosis at lower point on vena cava. Note circular movement of renal artery.

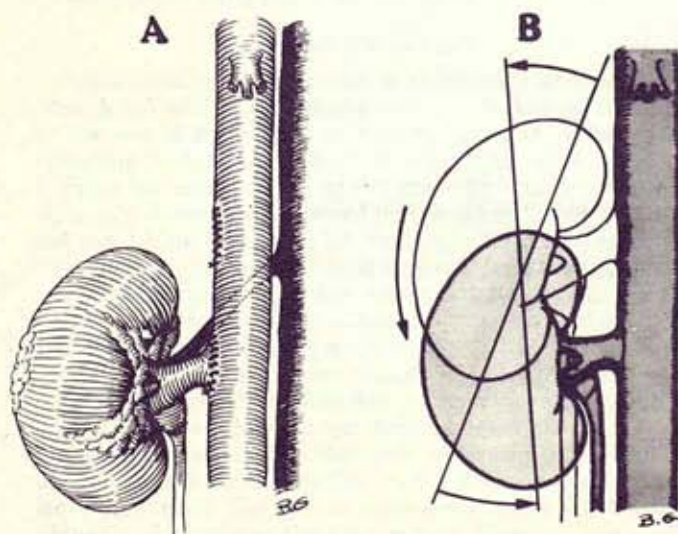


FIG. 2. A, pyeloureteral anastomosis is done after vein anastomosis. B, descent of right renal vein changes direction of major axis.

should be placed on the vena cava (fig. 1, B) and the renal vein is sectioned with its outlet. Continuous 5-zero sutures are applied to the defect in the vena cava.

Although the average ischemia time is only 15 minutes the kidney is preserved from warm ischemia and possible thrombosis by placing it in hypothermia, using perfusion with an intra-arterial injection of a solution of intracellular ionic composition at 4C and cooling it externally (fig. 1, C).

The kidney is held by the artery only and it is moved along the vena cava until the maximum drop point is reached. At this point the return renal circulation is established by anastomosis of the renal vein to the vena cava, using continuous 5-zero sutures and trying to evert the edges (fig. 1, D).

After the vein anastomosis is done urinary re-establishment is achieved with 6-zero catgut (fig. 2, A). A minimum nephrostomy is done with multi-perforated silicone tubing.

As a result of this descent the lower part of the kidney is closer to the spine and its major axis changes direction (fig. 2, B).

RESULTS

The operation has been done on 6 patients, all of whom had considerable stenosis of the pyeloureteral junction and/or scar retraction of the pelvis or extensive stenosis of the lumbar

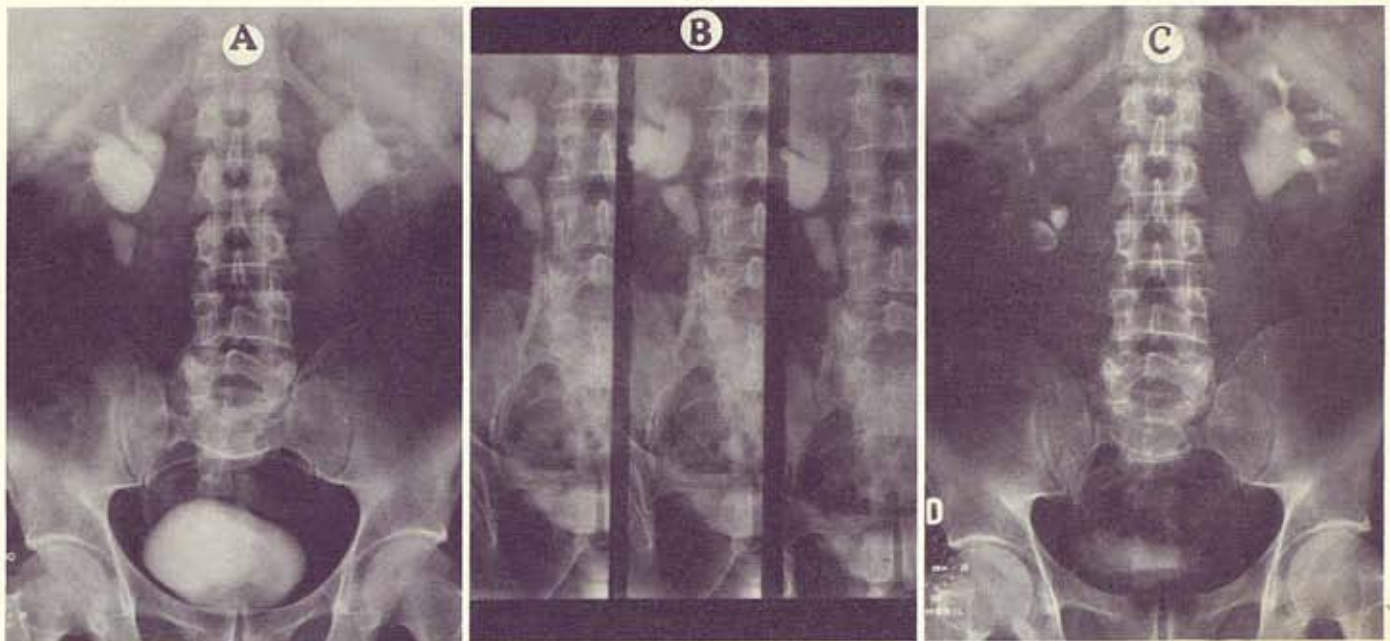


FIG. 3. A, preoperative IVP reveals hydronephrosis caused by narrow pyeloureteral junction and lumbar ureter after pyelotomy and longitudinal ureterotomy. B, preoperative IVPs from same patient. C, IVP after descent of renal vein with wide resection and ureteropelvic reanastomosis.

ureter owing to a previous operation for renal or ureteral stones (fig. 3). Ample resection and anastomosis were accomplished in every case, permitting re-establishment of urinary continuity without tension. There have been no postoperative complications.

REFERENCES

1. Gil-Vernet, J. M.: New surgical concepts in removing renal calculi. *Urol. Int.*, 20: 255, 1965.
2. Gil-Vernet, J. M.: Transverse ureterotomy. *J. Urol.*, 111: 755, 1974.